

HORSE SHOE FISTULA-IN-ANO TREATED WITH KSHARASOOTRA- CASE REPORT

Meena Rakesh Kumar¹ Dudhamal Tukaram Sambhaji² Gupta Sanjay Kumar³

Dept. of Shalyatantra, IPGT& RA, Gujarat Ayurved University, Jamnagar, India

ABSTRACT

Ksharasootra a medicated thread is used in ano-rectal disorders particularly in the management of fistula-in-ano in Indian system of medicine. In this study *Guggulu* based *Ksharasootra* was prepared by Apamarga Kshara (Ash of *Achyranthus aspera* Linn.), *Guggulu* (*Commepheria mukul*) and turmeric powder (*Curcuma longa* Linn.). A patient with horse shoe fistula-in ano at anterior part of anus was treated with application of *Ksharasootra* (Medicated thread). This case study demonstrates the utility of *Ksharasootra* in horse shoe fistula-in ano

Keywords: Apamarga Kshara, Bhagandara, Guggulu, Horse shoe fistula-in-ano, Ksharasootra

INTRODUCTION:

In Ayurveda, Bhangadara (Fistula-in-ano) is considered under the heading of eight major diseases (*Ashtomahagada*) due to its notorious nature.¹ Even today horse shoe fistula is more difficult to cure and if fistula is at anterior portion of anus that became worst. In surgery fistulectomy, fistulotomy, new techniques like fistula plug, and LIFT (Ligation of Inter-sphincteric Fistula Tract) are available options with their own limitations.² On other hand complications like incontinence and recurrence are more in cases of horse shoe fistula. Sushruta, the father of surgery described application of *Kshara* (alkaline ash) in *Bhagandara* (fistula-in-ano).³ Later on Chakrapani and Bhavmishra detailed the preparation and application of *Ksharasootra* in *Bhagandara* (fistula-in-ano).^{4, 5} In this study, a case of anterior horse shoe fistula-having external opening at 10 o'clock and 3 o'clock position

and internal opening at 12 o'clock position was treated with the *Ksharasootra* application. The *Guggulu* based *Ksharasootra* was prepared as per Ayurved Pharmacopia of India (API) guidelines.⁶

Case History:

A 20 years old male patient of *Vata-kaphaj Prakriti* visited in the OPD of Shalya Tantra for treatment of *Bhagandara* (Fistula-in-ano). The patient had complaints of intermittent perianal pain, perianal pus discharge and constipation since one year. On inspection at perianal region two external opening at 10 O'clock and 3 O'clock positions were noted. After probing it was found that tract of 3 o'clock position and 10 O'clock positions both were connected to the internal opening at 12 O'clock position. For conformation trans-rectal ultrasound (TRUS) was done and report showed that 5-6 cm long fistula in left perianal region and 18x13 mm sized collection in right perianal

region 3cm length fistula. Hence on the basis of clinical observations and TRUS the case diagnosed as anterior horse shoe fistula. The length of both external opening from anal verge was 3 cm and open internally below anorectal ring. The induration was noted at anterior perianal region having horse shoe fistulous track. Routine blood and urine examinations of patient were done and found within normal range. There was no previous history of surgery and other illness noted by patient. So patient was diagnosed as a case of *Bhagandara* (horse shoe fistula) and admitted in Shalya male ward for further management with *Ksharasootra*.

Method of Ksharasootra Application:

Pre operative:

1. Written inform consent was taken.
2. Prepare local parts of patients
3. Haritaki (*Terminalia belerica*) 5gm + Saindhav Churna 1gm with luke warm water two times a day.
4. Proctolysis enema was given in early morning before procedure.
5. Inj. T.T. 0.5cc IM and sensitivity test for inj. xylocaine intra-dermal was done.

Operative:

Patient was kept in lithotomy position on O.T. table after giving spinal anesthesia. Perianal part was painted with Beta-dine solution and sterile cut sheet was draped. Probing was done from external opening at 3 o'clock position and internal opening found at 12 o'clock position which travels up to 10 o'clock position anteriorly (horse shoe fistula). *Ksharasootra* threading was done from external opening 3 o'clock positions to internal opening at 12 o'clock position and both ends of thread were tied loosely. Simultaneously *Ksharasootra* threading was done from external 3 o'clock position to external 10 o'clock position. At 3

O'clock opening some part of tract was excised to reduce the time of treatment and due to induration. Hence two *Ksharasootra* threads one from external to internal and another from external to external were applied (Fig-1).

Post operative:

From next morning, sitz bath/*Avagaha sweda* (warm water + *Panchavalkala* decoction) was advised for two times in morning and evening.⁷ Diets like green vegetables, milk, fruits was advised. Patient was advised not to consume non-vegetarian, spicy and oily food, junk foods, alcohol. Patient was advised to avoid long sitting and riding/travelling. Haritaki 5gm + Saindhav Churna 1gm with luke warm water two times a day was prescribed if patient felt constipated.

Subsequent change of Ksharasootra: *Ksharasootra* was changed on weekly interval by inserting a new *Ksharasootra* in the fistula tract applying 2% xylocaine jelly till complete cut through of fistulous tract. During each change length of *Ksharasootra* thread was recorded to assess the progress of treatment. The initial length of 1st thread (external to internal) was 7 cm and that of second thread (external to external) was 10 cm.

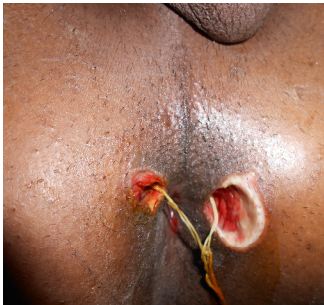Duration of Treatment: Total 2 months and 23 days for 1st thread (external to internal) and 3 months and 15 days for second thread (external to external) required for complete cutting and healing of fistulous tract (Fig-2). The time taken for complete cut through of track is differs due to length of track so the track external to external had taken more time due to more length. The unit cutting time (UCT) of fistulous tract in this case was found 0.62 cm per week.

DISCUSSION:

Sushruta advocated different treatment modalities to treat *Bhagandara* (fistula-in-ano) according to *Doshic* types of the fistula. Acharya Sushruta has mentioned that all types of *Bhagadara* are difficult to treat.⁸ In modern surgery also, it is known for its callus nature to cure and for its high recurrence rate with treatment like fistulotomy & fistulectomy. There are different modalities available for fistula but horse shoe fistula is difficult due to high recurrence rate. The ICMR (Indian Council of Medical Research) has been studied on *Ksharasootra* in fistula-in-ano and concluded better than conventional fistulectomy / fistulotomy with minimum recurrence rate.⁹

In this study, *Ksharasootra* was applied first time under spinal anesthesia and kept in situ and then *Ksharasootra* was changed after every week. The length of *Ksharasootra* was noted and found decreased on every change which suggested the cutting of tract. The applied *Kshara* on thread acts as anti-inflammatory and antimicrobial activity and renders chemical cauterization of tissue by virtue of its alkaline nature which facilitates cutting and healing.¹⁰ The pH of *Ksharasootra* is alkaline (pH-10.3); hence, it does not allow growth of bacteria in fistulous tract. This

cutting is



FigNo1Ksharasutra in fistulous tract

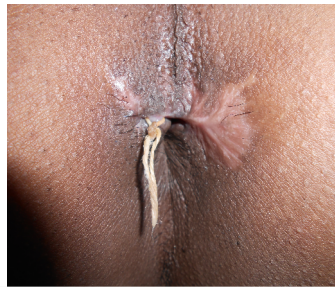


Fig No2. After 3 months of treatment

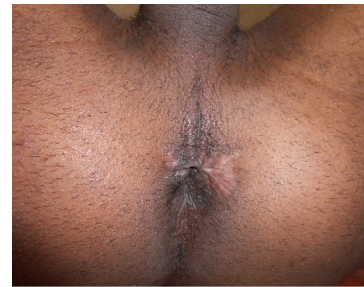

Fig No3 Complete cut through of tract

presumed by local action of *Kshara* and *Guggulu* during initial 1-2 days of its application which followed by healing in rest of the 5-6 days. The *Commepheria mukul* is well known for its anti-inflammatory, antibacterial property which helped in wound healing.¹¹⁻¹² *Curcuma longa* or turmeric powder minimizes reaction of caustics and helped for healing of tract.¹³ *Ksharasootra* has combined effect of these three herbal drugs (*Apamarga Kshara*, *Guggulu*, turmeric) and said to be unique drug formulation for cutting as well as healing of fistulous tract. Patient was advised to consult regularly on every week and after 3 months and 15 days patient was free from all symptoms of fistula with normal scar and without any complications (Fig-3).

CONCLUSION:

This single case report demonstrated that horse shoe fistula can be treated with *Guggulu* based *Ksharasootra* without any adverse effects. As it is a single case study so it require to study in more number of patients for concrete conclusion.

Acknowledgement: Prof. M.S. Baghel, Director, IPGT&RA, GAU, Jamnagar

REFERENCES:

1. Sushruta Samhita, Commentary Ayurved Tatva Sandipika, Ambikadata Shastri, Su.Su. 33/4, Chowkhambha Sanskrit Sansthan Varanasi,2001 12th ed. Page 35.
2. Johnson EK, Gaw JU, Armstrong DN. Efficacy of anal fistula plug vs. fibrin glue in closure of anorectal fistulas. Dis Colon Rectum 2006;49(3):371-76.
3. Sushruta Samhita, Commentary Ayurved Tatva Sandipika, Ambikadata Shastri, Su.Su. 11/7, Chowkhambha Sanskrit Sansthan Varanasi,2001 12th ed. Page 35.
4. Chakradata, Sharma PV, C. Chi. 5/148 Chowkhambha Publisher Varanasi, 2007 1st ed. Page 87
5. Bhavprakahs Commentary Vidyotini of Bhavmishra, Mishra BS, Madhya Khanda 5/144, Chowkhambha Sanskrit Bhavan Varanasi 2007 11th ed. Page 66.
6. Dwivedi AK, Chaudhry M, Kulshreshtha DK and Sarin JPS. Standarization of Ksharasootra. JRAS 1991;12 (1-2):85-92.
7. Sushruta Samhita, Commentary Ayurved Tatva Sandipika, Ambikadata Shastri, Su.Chi. 8/36, Chowkhambha Sanskrit Sansthan Varanasi,2001 12th ed. Page 47
8. Sushruta Samhita, Commentary Ayurved Tatva Sandipika, Ambikadata Shastri, Su. Ni. 4/4, Chowkhambha Sanskrit Sansthan Varanasi,2001 12th ed. Page 47.
9. Shukla NK, Narang R, Nair NG, Radhakrishna S, Satyavati GV. Multicentric Randomized controlled clinical trial of Ksharasootra (Ayurvedic Medicated thread) in the management of Fistula in ano. Indian J Med Res 1991;94:177-85.
10. Londonkar M, Reddy VC and Abhay Ku. Potential Antibacterial and Antifungal Activity of *Achyranthes aspera* L., Recent Research in Science and Technology 2011; 3(4): 53-57
11. Arora RB, Kapoor V, Gupta SK, Sharma RC. Isolation of a crystalline steroidal compound from *Commiphora mukul* & its anti-inflammatory activity. Indian Journal of Experimental Biology. 1971; 9(3): 403-404.
12. Saeed MA, Sabir AW. Antibacterial activities of some constituents from oleogum-resin of *Commiphora mukul*, Fitoterapia, Volume 75, Issue 2, March 2004, Pages 204-208.
13. Kohli K, Ali J, Ansari MJ, Raheman Z. Curcumin: A natural anti-inflammatory agent. Indian Journal of Pharmacology 2005; 37(3) 141-47.

CORRESPONDING AUTHOR

Dr. Dudhamal Tukaram Sambhaji
Assistant Professor , Dept. of Shalyatantra,
Institute for Post Graduate Teaching and
Research in Ayurveda, Gujarat Ayurved
University, Jamnagar, Gujarat-361 008, India
Email: drtsdudhamal@gmail.com