

THE STRUCTURAL STUDY AND PROGNOSTIC ASSESSMENT OF KURPARA MARMA

*Pande Prasad Prabhakharrao*¹

*Deshpande Pradnya Ravindra*²

¹Associate Professor, Dept. of Rachana Sharir

²Assistant professor, Dept. of Rachana Sharir

ABSTRACT

The marma (vital point) science is exclusively described in Ayurveda. The detail description regarding this has been found in texts of Acharya Sushrut, Charak and Vagbhat. This study has been carried out to study the kurpara marma structurally and prognostically. The methods of dissection, assessment of symptoms in the patients of elbow joint injuries and available literature were followed. In clinical survey, for its prognostic assessment total 100 patients of elbow joint injuries were observed carefully thrice, i.e. at the time of admission, after 2/3 months and finally after 04 weeks. The data was analyzed scientifically and it has been found that at the end, the patients are with the symptoms of weakness in forearm muscles which is similar to Kunitwa (weakness) mentioned by Ayurveda. The dissection confirmed its site and contents in it. From both studies, an attempt has been made to prove the Kurpara marma is sandhi marma (structurally) and vaikalyakara marma (prognostically).

Keywords: Marma, Kurpara marma, sandhi marma, vaikalyakara marma, kunitwa

INTRODUCTION

Ayurveda is an ancient system of medicine. The science deals with the whole study right from basic fundamentals up to the greatest achievements in the field of medicine and surgery. The *marma* science is one of the exclusive concepts of *Ayurveda* which has been well developed by keen observations, especially at the time of surgical procedures. These are very special and vital superficial points spread on the whole body surface. They are special because these points are the sites of '*prana*'¹ (Life processes). Moreover, *vishama spandana*² is also very phenomenal characteristics of these *marma* points. *Acharya Sushrut* in his *marma adhyaya*³, *Acharya Charak* in his *Trimarmiya siddhi adhyaya*⁴ and *chikitsa adhyaya*⁵, *Ashtanga hridayam* in his

*marmavibhaga*⁶ have made classical description throwing light on every aspect of *marma*.

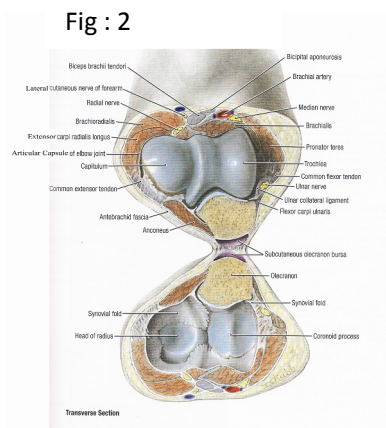
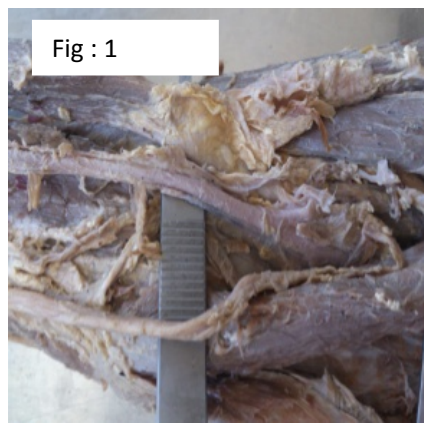
The *marmas* are very important from traumatological point of view. It has been observed that any trauma at this very point is more threatening or found to be delayed in recovery from injuries. *Acharya Sushrut* has mentioned the same in *marmabhigta lakshanas*⁷. The behavior of *marma* after trauma or injury is also depending upon its structural type. In present era, it has been observed that the injuries on these areas produce temporary or permanent, structural or functional deformity even after best treatments. So, to clear these doubts in our mind and to find out exact reason for these disabilities or deformities, the detail study of *marma* science is essential.

Objective –

1. To collect all the available literatures with respect to *sandhi* and *vaikalyakar marma*.
2. To locate the exact area of *kurpara marma* and find out contents in it.
3. To prove *kurpara marma* is *sandhi marma* structurally and *vaikalyakara marma* prognostically.

Materials and Methods –

1. **Review of literature :** All relevant references were collected in both *Ayurved & Modern Science*
2. **Experimental work :** It has been carried out in following two ways.
 1. Structural study & Clinical survey



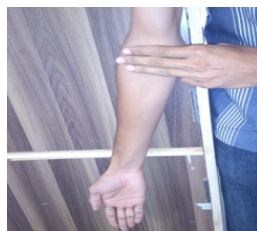For the structural study of *kurpara marma*, we have carried out dissection of either elbow joint of cadaver. We have used following materials.

- | | |
|-----------------------|-----------------------------|
| 1. Surgical scissor | 4. Forceps (simple & tooth) |
| 2. Lens | 5. Muscle Retractors |
| 3. Hand gloves & Mask | 6. Camera |

For clinical survey and observations, we used following materials.

- | | |
|---------------------|--------------------------------|
| 1) Measuring tape | 3) X-ray films of the patients |
| 2) Reports of X-ray | 4) Camera. |

Methods – Fig : 3



For structural study of *kurpara marma*, we have selected *three anguli*⁸ (digits) areas on either elbow joint of selected healthy individual in an anatomical position. Then three fully unidirectional extended fingers i.e. index finger, middle finger and ring finger were kept from above downwards on the elbow joint that these three well close with each other. We have confirmed this area as a site of *kurpara marma* as *Vagbhata* have mentioned--

- a) **Visham Spandana** – Pulsation of brachial artery medially to the elbow joint.
- b) **Pain on pressure** – Felt tingling numbness on putting pressure posterior to the medial condyle of humerus because of presence of ulnar nerve. For clinical survey, we have selected 100 patients of elbow joint injuries of falls, burns, accidents, sports injuries from civil Hospital, Akola and Gadda Orthopedic and Trauma centre, Digras (M.S.), irrespective of age, sex, religion and occupation.

The patients selected are—

1. Acute injury of elbow joint
2. The patients having history of falls on elbow joint more than 2-3 times.
3. The patients of sports injuries.

The patients excluded from the study are---

- 1) Dumb and deaf patients
- 2) Unconscious patients
- 3) Patients of arthritis

Observations – Table 1:

1. In these patients, we have observed following signs and symptoms.

Sr.No.	Sign / Symptom	No of Patients	Percentage
01	Pain at elbow joint	100	100%
02	Swelling at elbow joint	100	100%
03	Loss of muscle power in forearm	00	00
04	Restricted flexion of elbow	100	100%
05	Restricted extension of elbow	100	100%
06	Tingling Numbness	09	09%
07	Muscle Atrophy	00	00
08	Hand grasping power	00	00
09	Forearm sensory loss	00	00

Table 2:

2. All these selected 100 patients of elbow joint injuries were diagnosed with the help of modern techniques (X-ray reports). These patients were of following injuries.

Injury diagnosed	No of patients	Percentage
#of olecranon	12	12%

These patients were examined completely with the help of prepared case proforma. They were assessed in following manner-

- 1) Assessment at the time of admission
- 2) Assessment after 2-3 months
- 3) Reassessment after 04 weeks again.

Assessment Criteria – The signs and symptoms observed in the patients were assessed. (Mild / Moderate / Severe)

1. Pain at elbow joint
2. Swelling over elbow joint
3. Weakness in forearm muscle
4. Tingling Numbness
5. Inability in movements (flexion and extension)
6. Hand grasping power
7. Forearm sensory loss

All this data has been analyzed scientifically.

#Supra condylar	34	34%
#Intercondylar	28	28%
Posterior dislocation	06	06%
#Coronoid process	05	05%
Tennis elbow	15	15%

#-Fracture

Table 3:

These patients were assessed after 2-3 months. The following signs / symptoms were found.

Sr.No.	Signs/ Symptoms	No of Patients	Percentage
01	Pain at the elbow joint	02	2%
02	Swelling over the elbow joint	00	00
03	Restricted extension of the elbow	60	60%
04	Restricted extension of the elbow	42	42%
05	Tingling Numbness	18	18%
06	Weakness in forearm muscles	58	58%
07	Weakness in hand grasping	55	55%
08	Partially sensory loss over forearm	45	45%

Table 4:

The patients showing weakness in forearm muscles were analyzed on the basis of gradation

Grade	Findings	No of patients	Percentage
0	No contraction	00	-
1	Trace contraction	00	-
2	Active movement with gravity eliminated	01	1.72%
3	Active movements against gravity	00	-
4	Active movements against gravity & movement	44	75.86%
5	Normal power (Minimal Weakness)	13	22.41%

All these patients were observed again after 04 weeks. It has been found that maximum number of patients has followed the physio-therapies and exercises as advised by consultants. The following signs & symptoms were observed.

Table 5:

Sr.No.	Signs/ Symptoms	No of Patients	Percentage
01	Pain at the elbow joint	02	2%
02	Swelling over the elbow joint	00	-
03	Restricted extension of the elbow	07	7%
04	Restricted extension of the elbow	09	09%

05	Weakness in forearm muscles	58	58%
06	Partially sensory loss over forearm	41	41%
07	Weak Hand grasping power	55	55%

The above data shows in 58% of patients the symptoms remained was grade IV & V weakness in forearm muscles which also alters to the symptom of weak hand grasping power.

DISCUSSION:

The present research study has been carried out in following ways.

1. Review of literature
2. Experimental Research

According to *Sushrut*, the *kurpara marma* is one of the important *sandhimarma*¹⁰ (structurally) and *vaikalyakara marma*¹¹ (prognostically) located in three *anguli* (digits) area at the elbow joint. Initially the three *anguli* area is determined where the *kurpara marma* is situated as shown in figure.

To study the *kurpara marma* structurally, we have dissected the elbow joint of cadaver¹² and found that this area of three *anguli* is situated in between the medial and lateral epicondyles of humerus. The whole area is enriched with muscles, arteries, veins and nerves. Actually this area is supposed to be the base of cubital fossa. The structures found after the dissection of cadaveric elbow are-

1. Bicipital Aponeurosis is (inersion of biceps brachii), brachialis (floor of cubital fossa), brachioradialls (at the exterior part of elbow joint), flexor carpi ulnaris, flexor carpi radialis, palmaris longus (origin at medial epicondyle) – (*Mansa*)
Bifurcation of brachial artery into radial & ulnar artery, ulnar nerve, radial nerve & median nerve – (*Sira*)
2. Radial and ulnar collateral ligaments – (*Snayu*)
3. Lower end of humerus – Trochlea & capitulum, upper end of radius & ulna,

olecranon process & coronoid process.
– (*Asthi*)

4. Humeroulnar, Humeroradial and Radioulnar joints – (*Sandhi*)

Sushruta assumes that *marma* is a aggregation of *mansa*, *sira*, *snayu*, *asthi* and *sandhi*.¹³ We have found all these contents more or less at this site. *Vagbhata* has mentioned “*Vishama Spandhana*” and “Pain” as special characteristics of *marma* which has been already experienced and described at the time of determination of site of *kurpara marma*. It means that it satisfies the definition of *marma* by *Sushruta*. The important structure present in this region is naturally *sandhi* (joint) and other structures are surrounding and supplying to the joint. So we can say that *kurpara marma* is *sandhi marma*. In the clinical survey, we have selected 100 patients of elbow joint injuries who were already diagnosed as tennis elbow, fracture of olecranon, fracture of coronoid process, posterior dislocation, supracondylar fractures and inter condylar fractures. After observing these patients, the following signs and symptoms were found in most of the patients.

- 1) Pain at the elbow joint
- 2) Swelling over elbow joint
- 3) Weakness in forearm muscle
- 4) Inability in movements
- 5) Weak hand grasping power
- 6) Forearm sensory loss

In those patients, some structural deformity also observed in their X-ray films. All these patients again observed after the period of 2-3 months after getting

surgical/necessary treatment according to the diseases. The following symptoms remained with those patients.

- a) Weakness in forearm muscles.
- b) Restricted flexion
- c) Restricted extension
- d) Weak hand grasping power
- e) Tingling Numbness

The same 100 patients again observed after one month and the symptoms like inability to movements, tingling numbness have shown remarkable improvement, but the weakness in forearm muscles and weak hand grasping power remained with the patients. As quoted by Sushruta, 'Kunitwa'¹⁴ (weakness) is the ultimate sign produced after *kurpara marma* being traumatized. 'Kunitwa' means weakness at forearm that is what we found in most of the patients even after 03 months of time. So we can definitely consider the *kurpara marma* as *vaikalyakara marma* after its prognostic study.

CONCLUSION:

On the basis of dissection the three digits area of *kurpara marma* contains humeroulnar, humeroradial and radioulnar joints which means that *sandhi* is major component (approx – 40 %) and others are assisting in its movements & supply . Hence, we can conclude that *kurpara marma* is *sandhi marma*. In clinical survery, 100 patients selected of elbow joint injuries were observed at the time of admission, after 2-3 months and after 4 weeks. At the end, in those patients the symptoms remained are IV & V grade weakness in forearm muscles which is similar to 'Kunitwa' mentioned by *acharya Sushrata*.The weakness in forearm muscles occur when the brachial artery and peripheral nerves fails to supply in elbow joint injuries. The patients

showing these symptoms are of fractures of supracondylar & intercondylar in which the above said contents found to be damaged.¹⁵ This area is exactly the same which we have located for *kurpara marma*. Hence, we can conclude that the prognostic study of *kurpara marma* confirmed it as *vaikalyakara marma*.

Acknowledgement:

I really thankful to dean & head of the dept. of orthopedics, civil hospital Akola & Dr. A. M . Gadda, Gadda Orthopedic & trauma center, Digras Distt. Yavatmal(M.S.)

REFERENCES:

- 1) Sushrut Samhita of Sushrut with Nibandha Sangrah Commentary of Dulhanacharya edited by Vd. Yadavji Trikamaji, First Addition Chaukhambha Surbharati Prakashan, Varanasi, UP P.371
- 2) Astang Hridayam of Srimad Vagbhata, edited with Nirmala Hindi Commentary by Dr.Bramhanand Tripathi, Chaukamba Sanskrit Prakashan 2011 New Delhi.
- 3) Sushrut Samhita of Sushrut with Nibandha Sangrah Commentary of Dulhanacharya edited by Vd. Yadavji Trikamaji, First Addition Chaukhambha Surbharati Prakashan, Varanasi, UP P.369
- 4) Charak Samhita Vd.Manorama Hindi Commentary First Edition New Delhi Chaukhamba Sanskrit Prakashan 2003 P.945-962
- 5) Charak Samhita Vd.Manorama Hindi Commentary First Edition New Delhi Chaukhamba Sanskrit Prakashan 2003 P.622-667
- 6) Ashtang Sangrah by Vagbhata, Acharya S.S. Shashilekha, Sanskrit

- Commentary Dhishagaharya Second Edition Varanasi Chaukhamba Sanskrit Prakashan 2006.
- 7) Sushrut Samhita of Sushrut with Nibandha Sangrah Commentary of Dulhanacharya edited by Vd. Yadavji Trikamaji, First Addition Chaukhambha Surbharati Prakashan, Varanasi, UP P.372
- 8) Sushrut Samhita, Sharir Sthana, Sanskrit text with Ayurveda Rahasya Dipika Hindi commentary by Dr.B.G.Ghanekar, Meherchand Lacchmandas publications 2002, New Delhi India. P.200
- 9) Hutchison's Clinical Methods edited by Michel Glynn and William M Drake, Saunders Elsevier 23rd Edition Published 2012, P.303
- 10) Sushrut Samhita, Sharir Sthanam, Sanskrit text with Ayurveda Rahasya Dipika Hindi commentary by Dr.B.G.Ghanekar, Meherchand Lacchmandas publications 2002, New Delhi India. P.185
- 11) Sushrut Samhita, Sharir Sthanam, Sanskrit text with Ayurveda Rahasya Dipika Hindi commentary by Dr.B.G.Ghanekar, Meherchand Lacchmandas publications 2002, New Delhi India. P.185
- 12) Cunningham's manual of practical Anatomy Vol.1 by G J Romanes, Oxford Medical Publication, 15th edition P.104-106
- 13) Sushrut Samhita of Sushrut with Nibandha Sangrah Commentary of Dulhanacharya edited by Vd. Yadavji Trikamaji, First Addition Chaukhambha Surbharati Prakashan, Varanasi, UP P.371
- 14) Sushrut Samhita of Sushrut with Nibandha Sangrah Commentary of Dulhanacharya edited by Vd. Yadavji Trikamaji, First Addition Chaukhambha Surbharati Prakashan, Varanasi, UP P.371
- 15) Essential orthopedic J. Maheshwari, Mehata Publisher, 3rd Edition, Jan.2002 P.79-89

CORRESPONDING AUTHOR

Dr. Pande Prasad Prabhakharrao
Associate Professor, Dept. of Rachana
Sharir
Email:dr_prasadpande@rediffmail.com
