

## KSHARA SUTRA THERAPY A BOON FOR PILONIDAL SINUS – A CASE STUDY

**Shyamsundar Upadhyaya. B. R<sup>1</sup>, Shankar.S<sup>2</sup>, S.V.Shailaja<sup>3</sup>**

<sup>1</sup>Final year M. S scholar, <sup>2</sup>Reader, <sup>3</sup>Professor & HoD,

Department of PG studies in Shalya Tantra of Sri Kalabyraweshwara swamy Ayurvedic  
Medical College Hospital and Research Center. Bangalore, Karnataka, India

### ABSTRACT

Pilonidal sinus (*Nadi vrana*) is acquired condition and seen in adult males and hardly seen in females. Due to friction between clothes and body, hairs break off and collect in cleft and further it penetrates the soft and moistened skin at that region or enters the opening of mouth of sudoriferous glands. After initial entry dermatitis and inflammation start around the loose hairs and sinus will be formed further. This disease is recurrent in nature which makes it more difficult for treatment. So, it produces inconvenience in routine life. The concept of *kshar sutra* has been explained in the context of *Nadi vrana (sinus)* by *Acharya Sushruta*. In present study the case presenting with complaints of Pain and foul smelling discharge from low back which was diagnosed as pilonidal sinus, not willing to undergo surgery and opted for the *kshar sutra*. The patient received in the OPD of SKAMCH RC and has been treated with the *kshar sutra* prepared in SKAMCH & RC by following the standard protocol of preparation. The patient is treated on OPD basis with weekly change of thread. The patient recovered well with complete excision of the tract within span of 10 weeks.

**Key words-** Pilonidal sinus, *Nadi vrana*, *Apamarga Kshara sutra*

### INTRODUCTION

*Ayurveda* the indigenous system of medicine is an integral part of Indian culture. The ancient *acharyas* from centuries had used polyherbal and herbo-mineral formulations for prevention and treatment of various ailments. In the present era, there is noted insurgence demand among the consumers because of holistic approach.

*Pilonidal sinus* is a common condition which we see in current surgical practice, which is raising problem and challenge to practicing surgeon, it is a sinus track which commonly contains hair. It occurs under the skin between the buttocks (the natal cleft) at a short distance above the anus. The sinus track goes in a

vertical direction between the buttocks. Most cases occur in young male adults<sup>1</sup>. The origin of Pilonidal disease is not fully understood, although hormonal imbalance, presence of hair, friction and infection are often implicated. The most commonly used therapy is surgery including wide excision and healing by secondary intention. However, post operative recurrence following surgery is high, leading to frequent and time-consuming wound care. Hence, there is a need to evaluate the role of the other alternative/innovative techniques for the management of this challenging disease so as to minimise recurrence, make it cost

effective, with improved acceptability & minimum hospitalization.

'Sushruta Samhita', describes a condition 'Shalyaja Nadi Vrana' which is similar to 'Pilonidal sinus'. 'Shalyaja nadi vrana' is a track which is described to be due to presence of pus, fibrosed unhealthy tissue & hair etc. inside left unnoticed. Sushruta has advocated a very unique minimally invasive treatment i.e. 'Kshara Sutra' procedure for management of Nadi vran (PNS)<sup>2</sup>. Kshara sutra is a medicated thread (Kshar sutra, derived from Sanskrit word- Kshara means, to cut; Sutra means thread) coated with herbal drugs and rendered alkaline. The introduction of Kshar Sutra into Fistulous tract gradually dissolves the fibrous tissues, drain the pus and enhance the granulation in the tract.

#### Materials & Methods:

In the preparation of Apamarga Kshara Sutra, (medicated thread) three herbal drugs had been taken namely-

1. Latex of Snuhi (*Euphorbia nerifolia*)
2. Alkaline powder (Kshara) of Apamarga (*Achyranthes aspera*)
3. Powder of Haridra (*Curcuma longa*)

#### Preparation of Apamarga kshara

The Whole part of dried Apamarga (*Achyranthes aspera*) approximately of 10 kg was taken which are incinerated into ashes, and then it was allowed to cool by itself. The whole ash (approx 1 kg) was collected and mixed with six times of water and stirred well, and later allowed to settle overnight. Then this is filtered through double folded sterilized muslin cloth for twenty one times and residue was discarded. The filtrate which usually looked amber color was heated on slow controlled continuous heat until there is evaporation of water content and attains powder form. Then it is removed from fire and transferred into separate container with lid and stored for use<sup>3</sup>.

The processed kshara will be having specific properties which are explained in the below table (table no. I).

**Table No I: Properties of kshara-**

Rasa	Katu
Veerya	Ushna
Varna	Shukla
Guna	Somya, Thiksna, agneya.
Doshagna	Tridoshaghna
Karma	Dahana, Pachana, Darana, Vilayana, Shodhana, Ropana, Shoshana.

#### Preparation of Kshara sutra

For the preparation of thread, surgical linen thread Barbour number 20 was manually coated eleven times with the latex of Snuhi, followed by seven coatings of the latex and the alkaline powder of *A. aspera* alternatively and dried. In the final phase, three coatings of latex and Powder of *C. longa* was given alternatively. The thread thus prepared was sterilized by ultra violet radiation and placed in glass tube. The pH of the thread was ensured to be about 9.75, while the length was about 11-14 cm.

Other supporting materials used those include gauze, cotton swab, artery forceps, gloves, kidney tray, suture cutting Scissors.

#### Patient details

A 35 year old male patient presented with complaints of Pain and foul smelling discharge from low back region between the buttocks since 15 years. Initially he noticed mild swelling at natal cleft with intermittent dull aching pain which was there for 6 days . Later he noticed foul smelling pus discharge associated with mild itching in that area . He used to feel discomfort in this region during sitting and bending. He neglected it even though it used to interfere with his daily activities.

Whenever there was little injury to the area, pain and bleeding was noticed for which he consulted a local physician to get rid of pain.

Two years before again he noticed mild swelling at right side of natal cleft with intermittent dull aching pain which was there for one week followed by foul smelling pus discharge. Symptoms used to aggravate by travelling on his bike and profuse sweating. when the pain and foul smelling blood mixed pus discharge increased considerably, the local physician advised him to consult at higher center. So he approached Shalyatantra OPD in SKAMCH & RC on 1<sup>st</sup> December 2014.

- On examination – well built, moderately nourished, Pallor – Absent, edema – Absent, Icterus- absent, Cyanosis – absent, lymph nodes – no enlargement noticed,
- Respiratory system – NVBS, B/L EAE,
- Cardiovascular system – S1 & S2 heard.
- Gastrointestinal system – P/A – soft, non tender, BS ++.
- Per rectal – NAD

Examination of sinus -

### INSPECTION

- 1) Number of sinus- 6 Sinuses
- 2) Position of sinus:
  - 2 Primary openings in the midline of natal cleft just above the buttocks.
  - 4 Secondary openings seen right laterally.
- 3) Opening of the sinus
  - Presence of tuft of hairs seen
  - Margin – normal.
- 4) Discharge- Pus discharge present
- 5) Surrounding Skin-
  - Inflammation - present.
  - Scars – Absent
- 6) Smell- Foul smelling discharge.

### SINUS PROBING:

Two primary sinuses were inter connected with a depth of 2cms directed downwards. The secondary sinuses right laterally were connected to the primary sinuses and inter connected with each other. There was blood mixed pus and hair on withdrawal of the probe.

P = Primary sinus

S = Secondary sinus

P1- P2 interconnected

P1- S1interconnected

P2-S4 interconnected

S1-S2interconnected

S3-S4interconnected

### Laboratory investigations –

- Hb – 15.3gm%
- Tc – 9680 cells/cubic mm<sup>3</sup>
- Bleeding time – 2min 05sec
- Clotting time – 4min 45 sec.
- Prothrombin time – 12.8 sec.
- Activated partial thromboplastin time – 34.6sec.
- Random blood sugar – 104mg/dl.
- HBsAG – Non reactive.
- HIV 1 & 2 – Non reactive.
- ESR – 22mm/Hour.
- Ecg – Normal.
- CXR – PA view – Normal.

### Application of Kshara sutra

The *kshara sutra* prepared with *Apamarga* (*Achrynthes aspera*) as per standard protocol was used. Before application of *Kshara sutra*<sup>4</sup>, patients were advised to maintain proper local part preparation and general hygiene. Patient was placed in Knee elbow position and after aseptic preparation of the part, probing was done under local anaesthesia. Probe was passed into the P1 opening; gradually extended to the other opening and before taking it out, a sterile plain surgical linen thread Barbour number 20 was threaded into the eye of probe, present at tail end and then

probe was taken out through P2. Same procedure was repeated between S1 – S2 and S3 – S4 (Primary threading). One week later, the old thread was replaced by new *ksharasutra* by railroad technique. After replacement of the *Kshara sutra*, the patient was advised to continue his normal

routine work .The *Kshara sutra* was changed weekly.

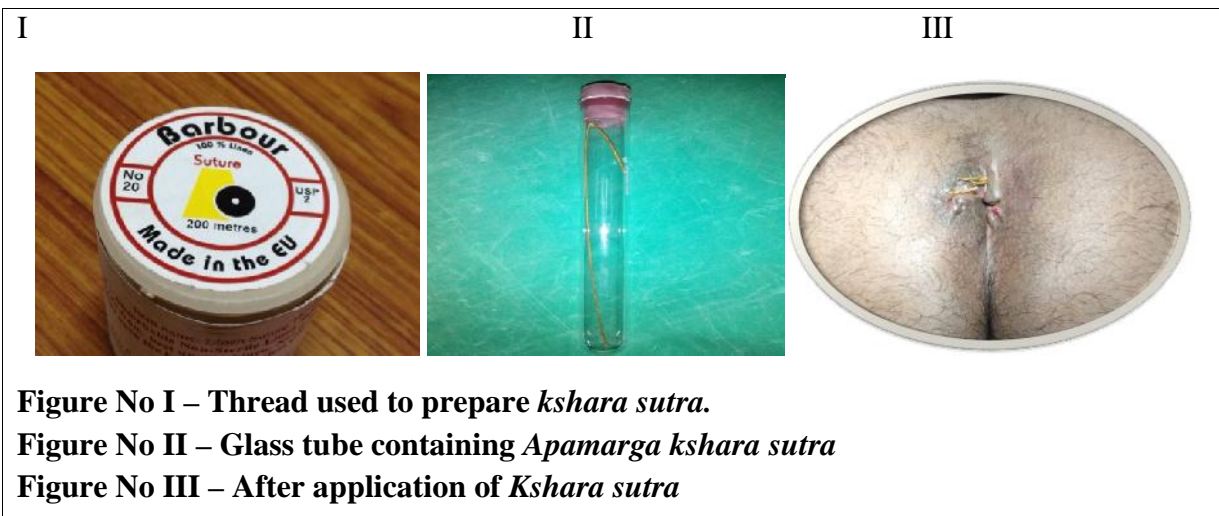
**RESULTS**

There was considerably changes found on various parameter which was as follows: --

**Table No II – Assement during the treatment**

Sr. No.	Date of thread change.	Discharge	Pain	Tenderness	Itching
1.	8 <sup>th</sup> Dec 2014	+++	+++	+++	++
2.	10 <sup>th</sup> Dec 2014	+++	+++	+++	++
3.	19 <sup>th</sup> Dec 2014	++	+++	+++	++
4.	24 <sup>th</sup> Dec 2014	++	+++	++	++
5.	7 <sup>th</sup> Jan 2015	++	++	++	++
6.	14 <sup>th</sup> Jan 2015	+	++	+	+
7.	21 <sup>st</sup> Jan 2015	+	+	+	Absent
8.	27 <sup>th</sup> Jan 2015	+	+	+	Absent
9.	3 <sup>rd</sup> Feb 2015	+	-	-	Absent
10.	10 <sup>th</sup> Feb 2015	-	-	-	Absent
11.	18 <sup>th</sup> Feb 2015	-	-	-	Absent

The complete excision of Primary tract was achieved in span of 7 weeks and for secondary tract excision achieved in 10 weeks.



**Figure No I – Thread used to prepare *kshara sutra*.**

**Figure No II – Glass tube containing *Apamarga kshara sutra***

**Figure No III – After application of *Kshara sutra***

**DISCUSSION**

- The management of pilonidal sinus in an effective manner has always been a challenge to the surgeons world over.
- The conventional operative treatment of pilonidal sinus is to lay open or completely excise the fistulous track and allow healing by open granulation.

- Pilonidal sinus is known to be predominantly a Jeep drivers disease
- The *Kshara Sutra* therapy in pilonidal sinus can be considered as preferable method of treatment for the following reasons –
  1. It is technically easy, safe, simple and does not require any special paraphernalia. It can be carried out in the outpatient department, as most of the cases do not

require any anaesthesia also, it is considered as cost-effective treatment as compared to others.

2. It does not require hospitalisation and patients could continue with their normal routine work, thus patient's social, psychological and economic status is not disturbed during the treatment.

3. The rate of recurrence after the treatment is negligible as compared to its various other seton and surgical management.

4. It is an ideal management for the patients of old age or having respiratory or cardiovascular diseases and or otherwise unfit for surgery.

5. No systemic side effects are encountered with *Kshara Sutra* therapy, although transient infection, local burning sensation, mild pain, itching and slight indurations are observed, which rarely need medication.

6. Post-operative tissue damage and scarring are minimal. The *Kshara Sutra* therapy, a unique method of drug delivery, most appropriate for healing the fistulous track offers an effective, ambulatory and safe alternative treatment in patients with pilonidal sinus .

## **CONCLUSION**

The results obtained were found very encouraging. Hence, application *kshara sutra* can be effective intervention in the management of Pilonidal sinus.

## **REFERENCES**

1. Das. S: A Concise Text Book of Surgery, Publisher Dr. Das. S, 5<sup>th</sup> edition reprinted-2009, Chapter 54, pp-1343, pg-1099.

2. Sushruta: Sushruta samhitha with commentary of Dalhana, edited by Vaidya Jadvji Trikamji Acharya, Chowkamba surbharati prakashan, Varanasi, reprint 2008, Chikitsa sthana, Chapter 1, Verse 29, pp -824, pg – 468.

3. Sushruta: Sushruta samhitha with commentary of Dalhana, edited by Vaidya Jadvji Trikamji Acharya, Chowkamba surbharati prakashan, Varanasi, reprint 2008, Sutra sthana, Chapter 11, Verse 11-14, pp - 824,pg - 46.

4. Sushruta: Sushruta samhitha with commentary of Dalhana, edited by Vaidya Jadvji Trikamji Acharya, Chowkamba surbharati prakashan, Varanasi, reprint 2008, Chikitsa sthana, Chapter 1, Verse 30- 33, pp -824, pg – 468.

## **CORRESPONDING AUTHOR**

**Dr. Shyamsundar upadhyaya B R**

Final year M. S scholar,

Department of PG studies, Shalya Tantra, Sri Kalabyraweshwara swamy Ayurvedic Medical College Hospital and Research Center. Vijayanagar, Bangalore, Karnataka, India

**Email:** shyamsundarupadhyaya@gmail.com

*Source of support: Nil*  
*Conflict of interest: None Declared*