

TO ELABORATE CONCEPT OF SEVANI WITH THE HELP OF MODERN ANATOMY

Dr. Budruk Pramod Appasaheb

M.D. Sharir Rachna, L.L.B.(spl), **Principal-** Hon.Shri. Annasaheb Dange Ayurved Medical College, Ashta. Tal- Walwa, Dist- Sangli, Maharashtra, India

ABSTRACT

Ayurveda gives new Idea about human being in case of Anatomy, Physiology & other subjects also. *Ayurvedokth Rachana Sharir* describes about various terminology. In fifth chapter of *Sharirasthan Susrut* described various parts of the body. Not only various parts of the body, but also number of these parts or organs, is nicely given in this *Sharir sankhya vyakarana sharir Adhayaya. Anaga, Pratnyaga, Twacha, Kala, Sira, Snayu, Dhamani* are described with its numbers & distribution of them. *Sivani* is the one of structure present in the body. There is *Sapta-Sevani* present in the body. Structure of *Sevani* & also importance of it is given by *Ayurveda*. Though *Sevani* is mentioned in one *sloka*, but it has very much important. Its importance is given by comparative study with modern Science. Division of the skull is done by these *sevani*, as given in modern science. *Sevani* word gives two references. First is a *sapt Shivayna* available for the *sevani* & second in case of *sandhi sharir*. There is confusion regarding various terms as *sevani* or *simant*. With the help of this article I am trying to clarify these concepts with the help of modern science.

Keywords: *Sevani, Septasevani, Sivani, Tunnasevani, Sutures*

INTRODUCTION

We know that structural & functional unit of the body is cell. These cells came together to form tissue. These tissue come together which have same work is called as organ. The chain of organs having same functions forms a system. The various systems come together to form body. Thus body is constituted by various types of cells. In *Ayurveda* the body is made of various physiological components like body, mind, *soul*. *Susrutachya* has nicely described about body. He mentioned various body structures available in the body as given in modern

science, these structures we can easily correlate with the structures of modern anatomy. But there are some structures which we can't match with modern anatomy. Sometime these terms are used as per necessity. As these terms came from *Ayurveda*, the aim of using these terms also mentioned in it, that is meaning should know everyone. To elaborate meaning of the Ayurvedic terminology is necessary for standardization of the subject and to clear concepts of these terms to the students, who are studying Ayurveda.

How to cite this URL: Dr. Budruk Pramod Appasaheb: To Elaborate Concept Of Sevani With The Help Of Modern Anatomy. International Ayurvedic medical Journal {online} 2016 {cited 2016 July} Available from:

http://www.iamj.in/posts/images/upload/1277_1283.pdf

Sapta Sevanya Sirasi Vibhakata Pancha,
Jivoya shefachasorekeka;
ta Parihartavya Shasatrena III.

According to *Charak*, *Vaidhya* is one who knows all the *Sankha* of the body or numberlogy of the body. He can treat all patient without fear & properly. *Susrut* has explained this numerological anatomy broader than *charak*. In *Sankhya Sharir Adyaya* he given description from *shadang sharir* to *Aparisankheya* (numerous) of *Parmanu* present in the body.

Sevani is one of structure which present in head region or *shirbhag* & also below the tounge & space between bases of penis to anal canal. There are seven *sevani*, out of 5 are present in the skull called sutures. Remaining one is present in the base of tongue called frenulum of tongue, and other is present on scrotal region called raphe of the scrotum.

In *sanskruit-hindi kosha* meaning of the *Sevani* or *sivani* is structure or line of demarcation or it called as *Sandhirekha*. It is the part which joints two parts of the body. It looks like sutures taken by needle. Such type of structure is present on the skull. It divides the skull in various regions. *Susrut* told that these *sevani* are five in numbers.

Also he told that these *sevani* or sutures should be protected, at the time of surgery. Injury to these structures will be fetal, hence he told that,

Taa: Pariharatavya Shasataren II

According to V.S. Apaté's *Sanskrit Shadakosha* meaning of the *Pariharatavya* is the part which should keep away or to preserve the part from injury by trauma or at the time of surgery.³

Shata Sirasiti II 4 .

According to *Susrut* six bones are present in the head. These bones separate in intrauterine

life & the movement of these bones is helpful at the time of delivery. Afterward these bones attach with each other keeping mark on it & these are called as *sevani*. Actually there are four bones in adult but in early age there are six bones. Hence *susrut* has described as six bones are present in the skull. There are frontal or *purakapalasti*, parietal or *Pashvakapalasti*, *Paschakapalasti* or occipital & *Sankhasti* or temporal bone.

Sevani word is also mentioned at the time of description of the *sandhi*, Type of *sandhi* is given as *Tunna Sevani*,

Ta Ato Sandhayosthavidha

Korodukhalasamudaga Pratara

Tunnasevaniyayasatunda

Mandal Shankhavarta.¹¹⁵

Ayurveda divides all joints of the body in above eight types. These types of joint are given as *kor*, *Udukhal*, *samudaga*, *Pratara*, *Tunnasevani*, *vayastunda*, *mandal* & *Shankhavarta*. *Tunna Sevani* is a suture type of joint. *Tunnasevani* is a *sevani* type joint which is present in the skull. It divides skull into various parts. There are five joints present in it.

Shirakati Kapaleshu Tunnasevanya.¹¹⁶

Mainly the *Tunnasevani* type of joint is present in case of skull bone. The bones which are flat means scapula and hip bone has or in case of skull or skull cap. In case of skull or skull cap stitch like joints are available. Especially the Joint when two flat bones meet together having serrate edges is called as *Tunnasevani Joint*.

Chinnanalpasevanam Tunnasevani

Tunnasevanyo nam paraspar

*Pedicinedanturdharabhi Nirmita Kanatarala Sandhayall*⁷

The edges of the Joining edges are denticulate appearance. These denticulate process meet each other to form uniform Joint such

type of joint is named as *Tunnasevani*. This is *sthir* joint or immovable joint. *Tunna* means Tailor or stiche like mark of wound. A structure which appears like stitches of tailor or mark on the clothes or mark remains after wound. This mark we can see on the skull not on the skin.

Simanta sevani *bahitwacha*
sirashi na drushate.118

Sevanya are not seen on the surface of the body or exterior of the head. It present below the skin. It is present only on the bone or exterior of skull.

MATERIALS AND METHODS

In the dissection hall of ADAMC Ashta skull and dead body used for observed and for dissection purpose. Instruments like scalp and blade, tooth forceps and plain forceps is used for dissection of scalp and to see *sevani* of the skull, as well as frenulum of tongue and rape of the scrotum is observed.

Firstly various references regarding *sevani* are collected; also references regarding skull sutures and importance of sutures are collected. After observation and discussion regarding *sevani* future conclusion is drawn.

Sevanya are not seen on the surface of the body or extension of the head. Hence it is present only on the bone or skull. According to *paribhasha koasha* meaning *sevani* means mark remains after wound. Hence *Tunnasevani* is mark on the skull, or mark like sutures or stitch marks like structure. This mark we can see on the skull.

Skull has 22 bones, it is divided into calvaria which surrounds cranial cavity containing brain and lower anterior part is facial skeleton. The bones forming calvaria are paired temporal bones & parietal bones unpaired frontal & occipital bones and small bones like sphenoid & ethmoid bones.9

Suture is process of joining two surfaces or edges & afterword line or stitch so formed. Anatomically it is line of junction or an immovable joint between two bones especially of the skull. The frontal bone, parietal bone, occipital bone is seen in a superior view of the skull. These bones make up the superior part of the calvaria or the calva (skull cap) 10

Following sutures are found in the skull.

1-Coronal suture- the unpaired frontal bone articulates with the parietal bones at the coronal suture.11

This suture divides skull into anterior and posterior parts. The lateral portion of the calvaria begins anteriorly with the frontal bone. In upper regions the frontal bone articulates with parietal bones by coronal suture.

2-Sagittal suture- the two parietal bones articulate with each other in the midline at the sagittal suture. This suture divides skull into right and left halves. This suture generally present in the midline of the body.

3-Lambdoid suture- the parietal bones articulate with unpaired occipital bone at the lambdoid suture. This suture present on posterior view of the skull.12

4- Squamous suture-This suture starts from pterion point. It is present in between temporal and parietal bones and ends at the point asterion. Temporal bone is a major contributor to lower portion of lateral wall of the cranium. 13

Frontal bone articulates with greater wing of sphenoid bone and also with parietal bone at the sphenoparietal suture. At the end of temporal bone articulate with sphenosquamous suture. Temporal bone articulates with sphenoid bone at sphenosquamous suture & with parietal bone superiorly at the squamous suture & mastoid bone attached with occipi-

tal bone by occipitomastoid suture. Parietal bone attaches with mastoid bone parietomastoid suture. Thus sphenosquamous suture, squamous suture, parietomastoid suture and occipitomastoid suture forms along suture¹⁴ This suture forms one of the *sivani* of skull.

Next part of *sevani* is present below tongue. The under surface of oral part of tongue lacks papillae, but has number of linear mucosal folds. A single median fold called frenulum of tongue is continuous with mucosa covering the floor of oral cavity overlies midline sagittal septum. On the each side of frenulum there is lingual vein and lateral to vein fimbriated fold is present.¹⁵

The remnant of the line of fusion between labioscrotal swelling in the embryo visible on the skin of scrotum as longitudinal midline raphe that extends from anus, around the scrotal sac & on the inferior aspect of the body of the penis called raphe of penis. The base of the raphe is continuous with frenulum of the glans to more loosely attached skin proximal to the glans.¹⁶

In case of female the labia minora each bifurcate forming a medial & lateral fold, the medial folds unite to form a frenulum of clitoris & that joins the glans clitoris. Also labia minora unite forming a small transverse fold, to the frenulum of the labia minora, it is also called as fourchette.¹⁷

DISCUSSION

Skull is most important part of the body. Brain has vital part of the body and it is placed in the skull. It is well protected by

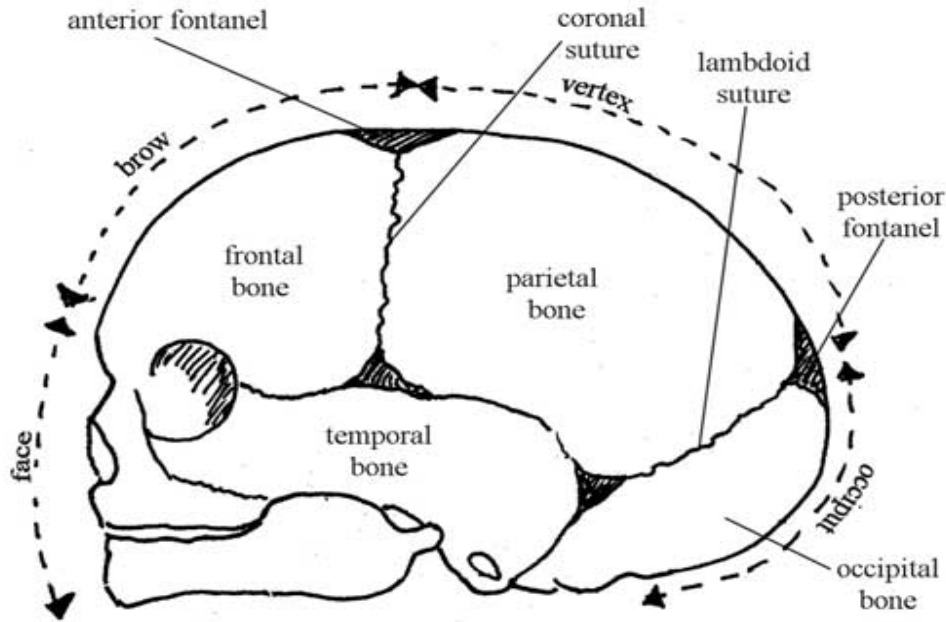
various covering as well as skull. Skull is the bony part which protects the brain from various impacts or shocks. When we observe skull, there are various types of sutures are present on it. It has 5 surfaces and upper part of the skull is called *Norma Superioris*. This part has the sutures on it. These sutures or marks are denticulate, serrate or squamous type.

When there are saw like edges of meeting surfaces then it is called as serrate joint. When there is one surface overlaps another surface at the time of joint then it is called as *sutura squamosa*. When plain edges meet together then it is called as plain sutures.

Susruta told that *Sevani* is also called as *sivani*. Sometime it is called as *simant*. We can observe the *sivani*'s on the skull. There are coronal suture, sagittal suture, lambdoid & squamous suture present on the skull. Comparative structures against is given in following table.

Second meaning of the *sevani* is said to be folds of skin or mucus folds. This has been seen in case of tongue. The fold present in the midline of tongue then it is called frenulum of the tongue.

This is very important structure because in case of any injury to this structure can hamper work tongue and this also creates difficulty in the pronunciation or speaking. If there is congenital shorting of frenulum then there may be sometime protrusion of the tongue. Hence *Susruta* has suggested preserving this structure.



Figure

Table

Sevani	structures	Structures present on	sevani	Important points
Sevani-1	Sagittal suture	In between two parietal bones.	1	From Bregma to Lambda point
Sevani-2	Coronal suture	In between frontal & parietal bone.	1	From right pterion to left pterion
Sevani-3	Lambdoid suture	In between parietal & occipital bone.	1	From right Asterion to left Asterion point
Sevani-4 and 5,	Squamous suture	In between frontal long temp - parietal & oripful bone.	2	From Pterion & Asterion point
Sevani-6	frenulum of tongue	floor of oral cavity.	1	sagittal septum and fimbriated fold
Sevani-7	raphe of scrotum in male	anus, around the scrotal sac.	1	frenulum of the glans penis and scrotum
	frenulum of clitoris in female	frenulum of the labia minora.	1	Frenulum of glans clitoris.

Also in case of the raphe of scrotum of male or frenulum of the clitoris and frenulum of the labia minora are structure resembles to structure mentioned in the sevani. These structures are also clinical importance as well as surgical important.

Second importance of the skull is that if there are no sutures, at the time of birth it will create problem in the birth of child. The boes of skull are flexible and overlaps each other for easy

delivery. If certain bones of skull grow fast, then also create deformity in the skull, due to this symmetry of skull will not be maintained. Also frenulum of the tongue connects gums to lips. Sublingual papilla & lingual veins are present near this structure. Injury to this structure creates bleeding & injury to salivary glands. Hence this structure is also preserved from injury at the time of surgery.

CONCLUSION

- 1) Sivani is a surgically important structure which is preserved at the time of surgery or any injury to it.
- 2) There are seven numbers of sivani. Out of five are present in the skull. These structures resemble the coronal suture, sagittal suture, lambdoidal suture and squamous sutures.
- 3) Structure of sivani is like a stitch mark or like a frenulum. Structure of sivani in the tongue is the mucus membrane of the frenulum of the tongue.
- 4) Second meaning of sevani is a structure that resembles the frenulum and it is like the raphe of the scrotum in males & the fold of the frenulum of the clitoris and the frenulum of the labia minora in females.
- 5) Thus the structures of the sevani are found on the skull, skin or mucus membrane. Whatever they may be, but Sushruta told to preserve these structures.

REFERENCES

1. Sushruta samhita –sharirasthanam.- Dr B.G. Ghanekar- Meharchand Laghamchand Publication, 4225- Ansari Road Dariyagan, New Delhi -110002. Reprint -2006 Sushruta samhita –sharirasthana Chapter 5\14 Page-154 .
2. Sanskrita-hindi Koash.- By V.S.Apte-Chaukhamba Sanskrita Bhavan. Chitra Theatre samor, Near Bank of Baroda Building, Post Box No. 1160 Varanashi. 221001 (India). ISBL- 978-81-89986-23-0 Reprint 2012 Page 1125.
3. Sanskrita-hindi Koash.- By V.S.Apte-Chaukhamba Sanskrita Bhavan. Chitra Theatre samor, Near Bank of Baroda Building, Post Box No. 1160 Varanashi. 221001 (India). ISBL- 978-81-89986-23-0 Reprint 2012 Page 592.
4. Sushruta samhita –sharirasthanam.- Dr B.G. Ghanekar- Meharchand Laghamchand Publication, 4225- Ansari Road Dariyagan, New Delhi -110002. Reprint -2006 Sushruta samhita –sharirasthana Chapter 5\21 Page-158.
5. Sushruta samhita –sharirasthanam.- Dr B.G. Ghanekar- Meharchand Laghamchand Publication, 4225- Ansari Road Dariyagan, New Delhi -110002. Reprint -2006 Sushruta samhita –sharirasthana Chapter 5\32 Page-165.
6. Sushruta samhita –sharirasthanam.- Dr B.G. Ghanekar- Meharchand Laghamchand Publication, 4225- Ansari Road Dariyagan, New Delhi -110002. Reprint -2006 Sushruta samhita –sharirasthana Chapter 5\32 Page-165.
7. Sushruta samhita –sharirasthanam.- Dr B.G. Ghanekar- Meharchand Laghamchand Publication, 4225- Ansari Road Dariyagan, New Delhi -110002. Reprint -2006 Sushruta samhita –sharirasthana Haranchand- Chapter 5\32 Page-166.
8. Sushruta samhita –sharirasthanam.- Dr B.G. Ghanekar- Meharchand Laghamchand Publication, 4225- Ansari Road Dariyagan, New Delhi -110002. Reprint -2006 Sushruta samhita –sharirasthana Indutika- Chapter 5\14 Page-154.
9. Grey's anatomy for students- by Richard L Drake, Wayne Vogl, Adam W.M. Mitchell –Elsevier Churchill Philadelphia Edinburgh London 2005 international edition ISBN-0808923064 –page no.- 763.

10. Grey's anatomy for students- byRichard L Drake, Wayne Vogl, Adam W.M. Mitchell –Elsevier Churchill Philadelphia Edinburgh London 2005 international edition ISBN-0808923064 –page no.- 769
11. Grey's anatomy for students- byRichard L Drake, Wayne Vogl, Adam W.M. Mitchell –Elsevier Churchill Philadelphia Edinburgh London 2005 international edition ISBN-0808923064 –page no.- 769.
12. Grey's anatomy for students- byRichard L Drake, Wayne Vogl, Adam W.M. Mitchell –Elsevier Churchill Philadelphia Edinburgh London 2005 international edition ISBN-0808923064 –page no.- 768.
13. Grey's anatomy for students- byRichard L Drake, Wayne Vogl, Adam W.M. Mitchell –Elsevier Churchill Philadelphia Edinburgh London 2005 international edition ISBN-0808923064 –page no.- 765.
14. Grey's anatomy for students- byRichard L Drake, Wayne Vogl, Adam W.M. Mitchell –Elsevier Churchill Philadelphia Edinburgh London 2005 international edition ISBN-0808923064 –page no.- 767.
15. Grey's anatomy for students- byRichard L Drake, Wayne Vogl, Adam W.M. Mitchell –Elsevier Churchill Philadelphia Edinburgh London 2005 international edition ISBN-0808923064 –page no.- 990.
16. Grey's anatomy for students- byRichard L Drake, Wayne Vogl, Adam W.M. Mitchell –Elsevier Churchill Philadelphia Edinburgh London 2005 international edition ISBN-0808923064 –page no.- 444.
17. Grey's anatomy for students- byRichard L Drake, Wayne Vogl, Adam W.M. Mitchell –Elsevier Churchill Philadelphia Edinburgh London 2005 international edition ISBN-0808923064 –page no.- 443.

CORRESPONDING AUTHOR

Dr. Budruk Pramod Appasaheb

M.D. Sharir Rachna, L.L.B.(spl),

Principal- Hon.Shri. Annasaheb Dange

Ayurved Medical College, Ashta.

Tal- Walwa, Dist- Sangli, Maharashtra, India

Email: pramodbudruk@rediffmail.com

Source of Support: Nil

Conflict of Interest: None Declared