

## SUPRASPINATUS TENDON RUPTURE- CONSERVATIVE MANAGEMENT BY HIRUDOTHERAPY- A CASE REPORT

Narkhede Yogesh Dnyandeo

Assistant Professor, Department of Shalyatantra, Sumatibhai Shah Ayurved Mahavidyalaya, Hadapsar, Pune, Maharashtra, India

### ABSTRACT

Rotator cuff injuries are the worse to treat as Shoulder joint is having complicated structure and many organs involving in Rotator cuff are prone to get injured in major or minor trauma to joint. Modern medical sciences recommend operative reconstruction surgery for rupture injuries of rotator cuff. But outcome of surgery many times lead to restriction of movements. So an Ayurvedic management was done in case of Supraspinatus rupture with Hirudotherapy (Leech Application), as the major reason for non-healing of these ruptures is less blood supply to these organs. Leech enhances blood supply to the site. So a result obtained in this case was very much satisfactory.

**Key Words:** Hirudotherapy, Supraspinatus Tendon Tear, Leech Therapy.

### INTRODUCTION

'It is worse to sprain than break it'. This is the statement so often made by patient and denied by surgeon.<sup>[1]</sup> Ligament injuries are worse to treat as pain severity and restricted range of movement are more in case of ligament injuries. Considering Rotator cuff injury it was present in 27.7% patients in one of the study conducted. Prevalence of Supraspinatus tendon tear increases with age. The risk factors for rotator cuff tear includes history of trauma, dominant arm and age.<sup>[2]</sup> Rotator cuff injury is a strain or tear in the rotator cuff muscles and is a common injury among baseball pitcher, volleyball players due to shoulder movements that involve vigorous circumduction. It also occurs as a result of wear and tear, aging trauma, poor posture, improper lifting and repetitive motions in certain jobs such placing items on a shelf above your head. This tendon is especially predisposed to wear and tear because of its location between the head of humerus and acromion of scapula which compresses the tendon during shoulder movements.<sup>[3]</sup> In modern Orthopedic sciences

management of Supraspinatus tendon tear is either by conservative method or by operative method. But in case of complete tear conservative treatment is completely rejected, because it is considered that it causes fibrosis formation and more serious problem. So to find alternative to this an Ayurvedic Treatment modality of leech application was carried out for conservative management of Supraspinatus tendon tear in order to avoid surgery.

**Case report:** A 62 year old female patient presented in O.P.D. with complaint of severe pain and restricted movements of Right shoulder joint. Pain at mid of right arm, Since 3 days.

Patient was telling history of jerk to the right shoulder while sitting on Bike. Patient had taken treatment at another hospital for three days as Analgesics, local application. Immobilization of shoulder with shoulder immobilizer. X ray of right shoulder was done before 3 days just after injury, it was normal (No obvious fracture was seen). But severity of pain and restricted ROM was increasing.

Personal history: Patient was having personal history of Hypertension since 4 years and was on regular treatment with controlled Blood pressure.

Clinical examination: Local examination revealed following findings: Range of movement of Shoulder- Abduction - Up to 20° Adduction – Complete, Circumduction – very painful and restricted.

- On palpation there was tenderness and crepitation at right shoulder, tenderness at right mid arm on lateral aspect.
- While abducting the right shoulder there was hunching of the shoulder.
- On passive ROM (Range of Movement) was full.
- No sensory loss over right upper limb. General examination: On general examination patient's B.P. was 140/90 , pulse was 84/min and systematic examination was normal.

Investigation: As X Ray of right shoulder was normal, patient was advised to do MRI of right shoulder which revealed following findings- MRI Right Shoulder: Complete tear is seen of supraspinatus tendon with retraction to the level of humeral head measuring 23 mm. Mild degenerative changes in form of erosions are noted involving greater and lesser tubercle. Mild supraspinatus tendinosis is seen. Fluid is seen in the subacromial bursa. Mild joint effusion is seen. Mild subscapularis tendinosis. (Fig.1)

Treatment: Patient was admitted for conservative management by analgesics and anti-inflammatory. Patient was given Tramadol, Seratiopeptidase, Diclofenac and immobilization with shoulder immobilizer. Orthopedic opinion was taken and patient was advised to undergo planned surgery for repair of supraspinatus tendon after 2-3 weeks. As patient was not willing for operative treatment, conservative treatment was continued with analgesics and immobilization and advised Hirudotherapy (Leech application) at right shoulder. Hirudotherapy was performed every third day at right

shoulder at site of insertion of supraspinatus tendon or at site of head of humerus by standard *Jalaukavacharan* method. Every time new leech was applied and the same leech was repeated after 7 days. This procedure was repeated for seven times. (Fig.2) The concomitant therapy with analgesics was continued for five days and discontinued after five days.

Observations:

- Patient did not required any analgesics after five days
- After 3 weeks of immobilization patient was allowed to do movements and clinical examinations revealed following observations-
  1. Adduction up to 100° without hunching.
  2. Can perform abduction up to 120° with taking support of accessory muscles without hunching.
  3. No tenderness/ no edema/ no swelling at right arm.
  4. Can perform circumduction once or twice without feeling pain.

## DISCUSSION

As discussed in introduction tendon or ligament injuries are difficult to treat as there is less blood supply to the tissue. So healing of ligaments after injury is always of great concern. It is well known that the ligaments which are allowed to repair conservatively produce larger undifferentiated scars. In tests of tensile strength it was been shown that the conservative repair of ligament tends to fail at the site of previous defect and it can be assumed that the less perfect apposition of diversified ends of ligament the more extensive is the scar tissue and the less satisfactory the repair. It has been suggested that the elastic areolar tissue is probably responsible for gripping the divided fibrils of the ligament, thereby preventing their coming together even when rupturing force has been discontinued.[3] Tendon is formed by the epimysium, perimysium and endomysium which continues with connective tissue that attaches skeletal muscle. All these three are connective tissue layers. Each

tendon organ consists of thin capsule of connective tissue that encloses a few tendon fascicles (bundle of collagen fibers).<sup>[5]</sup> A 'Critical Zone' of relatively decreased blood supply has been identified in the supraspinatus tendon about 1 cm proximal to its insertion into the greater tubercle of Humerus. Traction on the supraspinatus tendon by contraction of its muscle or by dependent position of Humerus attenuates the vessels in the critical zone which becomes relatively ischemic. This is the most common site of attritional changes. Also with advancing age there is decrease in the number and size tenoblasts and tenocytes as well as decrease in the water and mucopolysaccharides content. So rotator cuff injury follows a sequence of wear and tear and repair. Degeneration takes place in the critical zone with resultant inflammatory swelling of the cuff which may in turn cause impingement in the abduction. Progressive degeneration may lead to small or large tears in supraspinatus tendon. Small tears may heal but major tears are irreversible with persistent symptoms.<sup>[6]</sup> So considering this pathology of Supraspinatus tear, in addition to Modern conservative management Leech application (Hirudotherapy) was carried out for achieving rapid repair of the tendon. *Raktamokshan* (Bloodletting) is the half treatment described by Sushruta. From above discussion it is clear that in case of Supraspinatus tear there are chances of complication due to non or poor healing of ruptured tendon because of less blood supply to the critical zone in supraspinatus tendon. Therefore *Raktamokshan* (Bloodletting) procedure was performed in this patient in order to achieve good blood supply to tendon and rapid and good quality healing of it. A journal of internal medicine explained with research that treatment given only for seven days by leeches found wonderful response in the treatment of acute arthritis, inflammation and joint pain.<sup>[7]</sup> Professor Charles Lent, Leading biologists of us said that Leeches are useful in removing the blood from areas where tissue has been transplanted or

attached. Because when blood is accumulated tissue may die before it heals. Applying leeches to area once or twice a day for a week give capillaries time to grow across sutures and restores blood circulation.<sup>[8]</sup>

Biological active substances present in Saliva of medicinal leeches can restore blood circulation in the nude of inflammation to remove an ischemic organ to provide capillary tissue exchange and to improve immune protection and regeneration of tissue. The therapeutic effect is not only by loss of blood but also by the secretions which the leech emits in to the blood.<sup>[9]</sup> So in this case of supraspinatus tear when leeches were applied over the site of Supraspinatus tendon and after three weeks when joint was evaluated, it showed very good progress and increased range of movement which was not excepted by only conservative management as per modern sciences. The operative that is repair of supraspinatus tendon suggested by orthopedic surgeon was also not required and patient achieved good range of movement,

**Probable mode of action:**

- In this case of supraspinatus tendon tear, there is chances of poor healing because of 'critical zone' in the tendon which is having less blood supply
- If the blood supply is maintained and good circulation and oxygenation is maintained the ruptured tendon may repair faster and better.
- When leeches are applied near to this 'critical zone', due to presence of Antithrombin, antitrypsin and antichymotrypsin in saliva of leech there is improved blood supply as well as reduced inflammation at the rupture site.
- Also Hirudin present in saliva can reduce inflammation in arthritis patient by inhibiting ITNG protein, a derivative of synovial stimulatory protein.<sup>[10]</sup>
- All these improve healing process of ruptured tendon thereby restoring its original strength up to the fair extent and achieving good outcome with conservative management of Supraspinatus tear.

## CONCLUSION

In this case of Supraspinatus Tear if leech therapy is applied simultaneously with immobilization, good reconstruction of tendon can be achieved and range of movement of shoulder can be regained earlier with good quality.

## REFERENCES:

1. J.N. Willson; Watson- Jones Fracture and Joint injuries; Seventh edition: Elsevier Publication-2009: Delhi: 26
2. Yamamota A, Takagishi K, Osawa, Yangawa T, Nakajima D, Shitara H, Kobayashi T; Prevalence and Risk factors of Roatator Cough tear in general population; J. Shoulder Elbw Surgery; 2010 Jan; 19(1) : 116-20
3. Gerad J. Tortora, Bryan, Derrickson; Principles of Anatomy and Physilogy; Eleventh edition; John Wiley and sons; 2006; United states of America: 276
4. J.N. Willson; Watson- Jones Fracture and Joint injuries; Seventh edition: Elsevier Publication-2009: Delhi: 27
5. Gerad J. Tortora, Bryan, Derrickson; Principles of Anatomy and Physilogy; Eleventh edition; John Wiley and sons; 2006; United states of America: 292.
6. G.A.G Decker, D.J. duPlessis; Lee Mc Gregor's Synopsis of Surgical Anatomy;

Twelfth edition; Varghese Publishing house; 1999; Dadar, Bombay: 444-445

7. Dr. H.L. Sharma, Dr. (Smt) Sudha Sharma; Kayacikitsa Body Purification Therapy ( Panchakarma)- Part I; First Edition; Chaukhamba Oriantalia; 2006; Delhi:
8. Dr. Vasant C. Pati; Principles and practice of Panchakarma; Third editin; Atreya Ayurveda Publication; 2012; Ilkal (Karnataka): 533
9. Dr. Vasant C. Pati; Principles and practice of Panchakarma; Third editin; Atreya Ayurveda Publication; 2012; Ilkal (Karnataka): 538
10. A.M. Abdulkadar, A.M. Ghawi, M. Alaama, M. Awang and A. Merzouk; Leech therapeutic application ; Indian Journal of Pharmaceutical Sciences, V. 75/2; March April 2013: 123-137.

## CORRESPONDING AUTHOR

**Dr. Yogesh Dnyandeo Narkhede**

Assistant Professor, Department of Shalyatantra, Sumatibhai Shah Ayurved Mahavidyalaya,

Hadapsar, Pune, Maharashtra, India

Mail:sanjeevanihospitalpune@rediffmail.com




Fig. 1

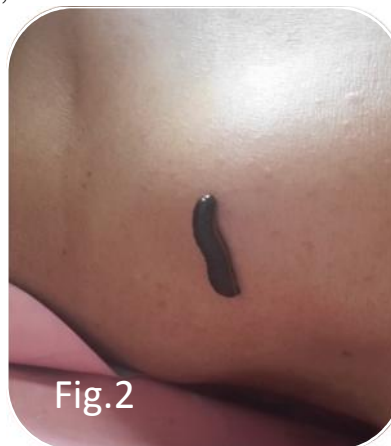

Fig.2

Source of support: Nil  
Conflict of interest: None Declared