

UNILATERAL VARIATION OF GREAT SAPHENOUS VEIN- A CADAVERIC STUDY

Arya ashok¹, Swapna kumary²

¹PG Scholars, ²Associate professor

Dept of Rachana Shareera

Alva's Ayurveda Medical college and Hospital Moodbidri, Karnataka, India

Email: unnimayamatramkott1991@gmail.com

ABSTRACT

The Great saphenous vein (*GSV) is a large superficial vein which is visible on the medial side of the thigh and leg. During our routine dissection a significant unilateral variation in the position of *GSV was observed at Alva's Ayurvedic medical college Moodbidri. The vein was not superficial at the thigh region. The aim of this article is to provide and define the variation of position of *GSV and its anatomical relation obtained from human cadaver. The dissimilarity in position of *GSV is very important in surgical and clinical practice. The detailed explanation about the variation will be carried out in this paper.

Keywords: Great saphenous vein, superficial vein, varicose vein.

INTRODUCTION

The lower extremity venous system includes the superficial, deep, and perforating veins. The veins of the lower extremity are classified according to their relationship to the muscular fascia and are located in either the superficial or deep compartment. The superficial venous system includes the reticular veins as well as the great and small saphenous veins and their tributaries¹.

GREAT SAPHENOUS VEIN

Normally, all superficial veins are thought to course in the adipose tissue between the dermis

and the deep fascia. Great Saphenous Vein (*GSV) secure firmly in position to the deep muscular fascia by a connective lamina that separates it from the superficial layers of the subcutaneous tissue. Anatomic investigations reveal that this lamina is a portion of the "membranous layer of the subcutaneous tissue" and it is termed as *saphenous fascia*.^{2,3} This lamina fuses with the deep fascia and delimits a flat, fatty space called *saphenous compartment*⁴ which includes the *GSV and the accompanying arteries, nerves, and lymphatics.

COURSE

The *GSV is the longest vein in the body, originates from the dorsal vein of the big toe merges with the dorsal venous arch of the foot. After passing in front of the medial malleolus, it runs up the medial side of the leg. At the knee, it runs over the posterior border of the medial epicondyle of the femur bone. The *GSV then courses anteriorly to lie on the anterior surface of the thigh before entering an opening in the fascia lata called the saphenous opening. It forms an arch, the saphenous arch, to join the common femoral vein in the region of the femoral triangle at the sapheno-femoral junction. The point where the *GSV empties into the common femoral vein is called the Saphenofemoral Junction (SFJ). A typical *GSV contains an average of 7 valves throughout its entire length, and it is the most common superficial vein to develop venous reflux⁵.

TRIBUTERIES

- At the ankle it receives branches from the sole of the foot through the medial marginal vein.
- In the lower leg it anastomoses freely with the small saphenous vein, communicates by perforator veins (Cockett perforators) with the anterior and posterior tibial veins and receives many cutaneous veins
- Near the knee it communicates with the popliteal vein by the Boyd perforator.
- In the thigh it communicates with the femoral vein by perforator veins (Dodd perforator) and receives numerous tributaries; those from the medial and posterior parts of the

thigh frequently unite to form a large accessory saphenous vein which joins the main vein near the sapheno-femoral junction.⁶

- Near the fossa ovalis it is joined by the superficial epigastric, superficial circumflex iliac vein, and superficial external pudendal veins.

Tributaries of the *GSV are superficial to the saphenous space and the saphenous fasci⁷. These veins are visible on the surface of the limb even if they are not varicose. When the tributaries are large, they may be erroneously considered to be a portion of a double or duplicated *GSV.⁸

The duplication of the *GSV was explained by the different authors. In this particular case, unilateral variation in position of the *GSV was observed.

CADAVERIC STUDY

The observation of variation was done during the routine dissection of lower limb region, at Alva's Ayurvedic Medical College Moodabidri. The cadaver was 60 year old male body without any deformity and well preserved. A curved incision was made from anterior superior iliac spine towards the pubic tubercle. A curved incision was made from pudental cleft towards the upper medial side of thigh and was extended till tibial tuberosity. After reflecting the skin and removing the fatty layer, *GSV was identified in the medial part of anterior surface of thigh. Its origin, course and tributeries on both sides were observed and identified.

OBSERVATION

During the routine dissection the variation of *GSV was observed unilaterally in the right thigh region of the male cadaver.

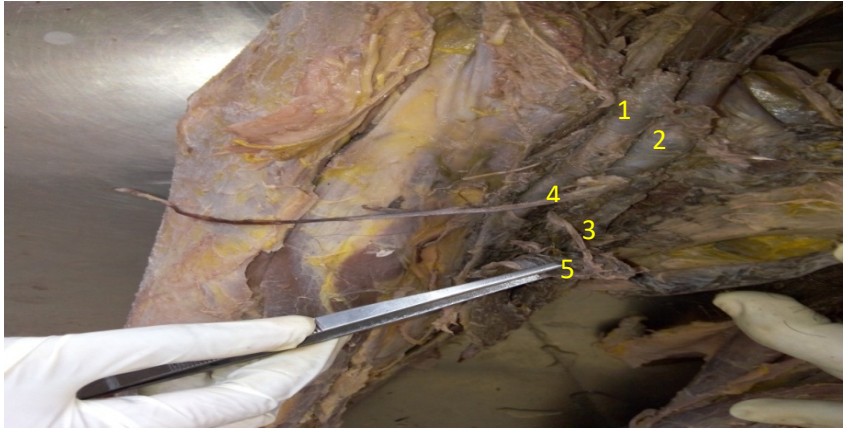


Fig 1:- variation of long saphenous vein in right leg

(1) Femoral artery (2) Femoral vein (3)*GSV (4) Accessory Saphenous vein (5) Flap of adductor longus

RIGHT THIGH –

A flap of adductor longus muscle was present completely overlapping the distal part of *GSV upto 15cm till sephano femoral junction. An accessory saphenous vein was also present which

joins *GSV near the sephano femoral junction running parallel and external to the *GSV. Accessory saphenous vein was also covered by adductor muscle flap.

Note:- Course of * GSV from dorsal vein of big toe till adductor longus muscle was normal.

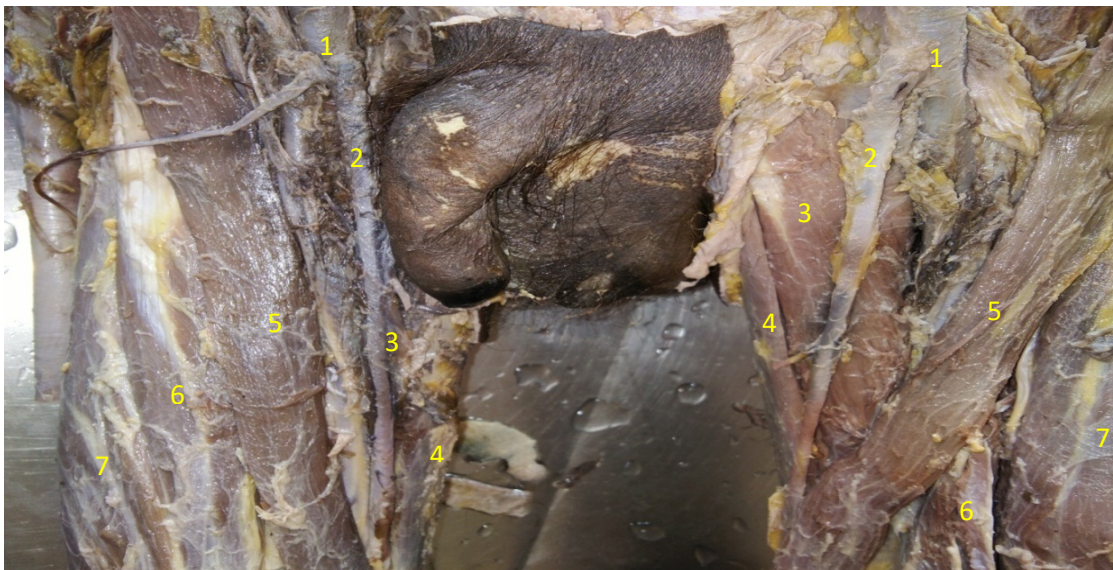


FIG 2: Variation of *GSV in the right thigh where the muscle flap is removed and the normal left leg

(1) Femoral vein (2)*GSV (3)Adductor longus (4)Gracillis muscle (5)Sartorius (6)Rectus femoris (7)Vastus medialis.

RIGHT LEG –

The course of *GSV can be seen in between the adductor longus muscle fibres along accessory *GSV.

LEFT LEG - The course of *GSV is normal as mentioned earlier (which is superficial to adductor longus muscle)

DISCUSSION

The *GSV is the main truncal vein of the lower leg and drains blood from the inner part of the foot, the skin and fat of the front and inner aspect of the lower leg, and the inner part of the thigh.

Saphenous means evident, as the word suggests *GSV is a superficial vein, but in the present case the course of *GSV is not superficial and it passes in between the muscle fibres of adductor longus.

The knowledge of anatomy of *GSV is very much important in clinical and surgical practices for the following reasons:

CLINICAL IMPORTANCE:-

As the course of *GSV is in between the muscle flap of Adductor longus :

- a) Adduction and medial rotation of the thigh may compress *GSV and may cause thrombophlebitis.
- b) Contraction and relaxation of adductor muscle fibres may hinder the normal pumping of venous blood and may cause venous diseases like varicose veins and ulceration.

SURGICAL IMPORTANCE:-

*GSV is removed for auto transplantation in coronary artery bypass operations when arterial

grafts are not available or if many grafts are required, such as in a triple bypass or quadruple bypass⁹. *GSV is widely used in auto transplantation because and it has superior long-term patency compared to synthetic grafts and removal of the saphenous vein will not hinder normal circulation in the leg due to the presence of collateral circulation. In this case in the right thigh, stripping of *GSV cannot be done as it is overlapped by adductor longus muscle flap. Thus Position of *GSV is most important in surgical point of view.

The venous anatomy of the lower extremities is substantially more variable and complicated than the corresponding arterial anatomy. A thorough understanding of this anatomy is essential to an understanding of the underlying pathophysiology of chronic venous disease as well as its diagnosis and treatment

CONCLUSION

This kind of unilateral variations of long saphenous vein in relation to adductor longus muscle even though very rarely reported, but it has to be considered. These variations of *GSV may results in varicose veins; thrombophlebitis and it cannot be removed for auto transplantation in coronary artery bypass operations.

So the knowledge regarding anatomical variations about its origin ,tributaries and course of long saphenous vein needed to take care during surgery and to plan accordingly during various surgical interventions of this region, as well as for general practitioners in differentiating the clinical case of long saphenous vein.

REFERENCES

1. Somjen GM. Anatomy of the superficial venous system. *Dermatol Surg* 1995;21:35–45
2. Caggiati, A. Fascial relationships of the long saphenous vein. *Circulation*. 1999; 100: 2547–2549
3. Caggiati, A. Fascial relationships of the short saphenous vein. (In press) *J Vasc Surg*. 2001
4. Caggiati, A and Ricci, S. The long saphenous vein compartment. *Phlebology*. 1997; 12: 106–111
5. Moneta GL, Nehler MR. The lower extremity venous system: anatomy and physiology of normal venous function and chronic venous insufficiency. In: Gloviczki P, Yao JST, eds. *Handbook of Venous Disorders: Guidelines of the American Venous Forum*. 1st ed. London: Chapman and Hall Medical; 1996:3–26
6. Franceschi, C.; Zamboni, P. (2009). *Principles of Venous Hemodynamics*. Nova biomedical Books. pp.12–13. ISBN 978-1-60692-485-3
7. Caggiati, A. The saphenous vein compartments. *Surg Radiol Anat*. 1999; 21: 29–34
8. Cotton, LT. Varicose veins—gross anatomy and development. *Br J Surg*. 1961; 48: 589–598
9. Mamode, Nizam; Scott, Roy N (1999). Mamode, Nizam, ed. "Graft type for femoropopliteal bypass surgery". *Cochrane Database of Systematic Reviews (2)*: CD001487. PMID 10796649. doi:10.1002/14651858.CD001487

Source of Support: Nil

Conflict Of Interest: None Declared

How to cite this URL: Arya Ashok & Swapna Kumary: Unilateral Variation Of Great Saphenous Vein- A Cadaveric Study. *International Ayurvedic Medical Journal* {online} 2017 {cited November, 2017} Available from: http://www.iamj.in/posts/images/upload/4079_4083.pdf