

A CASE STUDY ON GUDABHRAMSHA (PARTIAL RECTAL PROLAPSE)

Azizahmad. I. Arbar¹, Sachchidanand², Sneha Pattanshetti³

Proffesor & HOD dept. of kaumarbhritya
Final Year PG Scholar Dept. of Kaumarbhritya,
Final year PG Scholar dept. of Shalya tantra
Shri KLEU's BMK Ayurveda Mahavidyalaya Belagavi, Karnataka, India

Email: sachchi77.raj@gmail.com

ABSTRACT

Rectal prolapse is defined as an extrusion of some or all of the rectal mucosa through the external anal sphincter. It usually occurs between 1-4 years of age, with the highest incidence in the first year of life. Most of the cases of prolapse are idiopathic. It usually occurs when the child begins standing and then resolves by about 3-5 years of age when the sacrum has taken its more adult type and the anal lumen is oriented posteriorly. Thus, the entire weight of abdominal viscera is not pushing down on the rectum as it is earlier in development. Approximately 10% of patients who experience rectal prolapse as children continue to be symptomatic into adulthood. Over 90% of children who experience rectal prolapse during the first 3 years of life respond to conservative treatment by age 6 years. Spontaneous resolution is much less likely in children who develop their first episode of prolapse after age 4 years. After a surgical rectopexy, continence is achieved in 92% of patients. Resective procedures are associated with decreased recurrence rates. Recovery of continence after surgery is not immediate and may take as long as 12 months. A case approached to KLE's ayurvedic hospital to Kaumarbhritya OPD, having age of 7 year old male child & was brought with complaint of feeling of mass per rectum since 6 years, abdominal pain & sometimes per rectal bleeding was noticed. He had no other complaints, his systemic examination was normal. On examination mass per rectum was seen. In Ayurvedic doctrines rectal prolapse is being explained in the heading of gudabhramsha. Acharya *Susruta* said that *pravahan* (excessive straining), *Atisar* (diarrhoeal disease), *ruksha*, *durbal deha* person (weak & malnourished) are the causative factors for the disease. Acharyas have explained about ghritha, pichu, & asava preparations rather than going for surgery. As per quotation mandagni is cause for most of disease, so Agni is treated first, hence here changeri ghritha is advised for deepana, & pichu with mushika taila, & vidanga being best krimihara, and hence vidangasava is preferred.

Key words- Prolapse, Gudabhramsha, Changeri ghrita, Mushika taila, Krimi

INTRODUCTION

Rectal prolapse in children is not uncommon & usually self-limiting condition to a certain degree in infancy. Paediatric patients are usually affected when younger than 3 years with the peak incidence is in the first year of life¹. Mucosal prolapse is more common than complete possibly because of poor fixation of sub-mucosa to mucosa³. The incidence of prolapsed rectum in children with cystic fibrosis approaches 20%⁴. Boys & girls are equally affected.

Rectal mucosal prolapsed is the exteriorization of the rectal mucosa through the anus. In the unusual occurrence when all the layers of the rectal wall. Most of the cases of rectal tissue protruding through the anus are prolapse and not polyps, intussusceptions or other tissue.¹

Most of the cases of prolapse are idiopathic. It usually occurs when the child begins standing and then resolves by about 3-5 years of age when the sacrum has taken its more adult type and the anal lumen is oriented posteriorly. Thus, the entire weight of abdominal viscera is not pushing down on the rectum as it is earlier in development.¹

Other predisposing factors include intestinal parasites, malnutrition, repeated diarrhoea, ulcerative colitis, pertussis, meningocoel, cystic fibrosis & chronic constipation these cases are mostly treated surgically¹.

The prognosis is generally good with appropriate treatment. Spontaneous resolution usually occurs in children with rectal prolapse who are aged 9 months to 3 years, 90% will need only conservative treatment. Untreated rectal prolapse can lead to incarceration & strangulation¹.

Acharya Susruta had explained rectal prolapse is in the heading of gudabhramsha⁵. Acharya Susruta said that *pravahan* (excessive straining), *Atisar* (diarrhoeal disease), *ruksha*, *durbal deha* person (weak & malnourished) are the causative factors for the disease. Excessive straining during defecation will cause the laxity of the muscles & also if faecal matter is harder then it may injure the rectal mucosa leading to pain which in-turn lead to constipation This constipation again a cause for the prolapse. In diarrhoeal disease anal rectal sphincter doesn't get enough time to relax as well as contract. Weak & malnourished persons will be deficient of healthy tissue hence they will lack in fat tissue in levator muscle which will directly supports the rectum to be in its position.

Case history

A 7 year school aged boy was brought to us with the complaint of feeling of mass per rectum since 6 years, abdominal pain & sometimes per rectal bleeding was noticed. For the same complaints they have visited many doctors but didn't get relief. Developmental history was found to be normal. Family history was not significant. General condition of the child was good, vitals were stable. Weight was 16.2kg which is lesser than the expected weight i.e. 20kg. Mild pallor was present. Systemic examination were also found to be normal. Local examination reveals presence of mass per rectum. No sinus, fissure in ano or other wound were found. Digital examination of rectum revealed hypotonic sphincter, there was no bleeding during the examination. No Piles mass, no other growth were found in the rectum. With these finding the case was

diagnosed as *Guda bhramsha* --- (partial rectal prolapse)

Treatment given was-

The treatment was planned in 2 phases-

Initial phase was intended for *krimihar chikitsa, ama nirharan, kostha sodhana* and perinial strengthening.

1st 3-days:

Oral medication	Panchkarma treatment	Physiotherapy
<i>Vidangaristha</i> ⁸ 10ml tid with water after food	<i>Udawartana</i> with <i>udavartana churna</i>	(perianal exercises)
<i>Gandharvahastadi taila</i> 20ml (with milk & <i>guda</i>)	<i>Sthanik nadi sweda</i>	(perianal exercises)

In 2nd phase of treatment has been adapted which was *Vyadhi pratyanyika chikitsa* as mentioned in classical text

4th day onwards:

Oral medication	Panchkarma treatment	Others
<i>Lajjalukalka</i> ½ tsp. Twice in a day ^{6, 13, 14}	<i>Changeri ghruta</i> ^{12, 16} <i>matra basti</i>	Physiotherapy (perianal exercises)
	<i>Mushika taila pichu</i> ^{9, 15}	<i>Gophana bandh</i> ^{10, 11}
	<i>Avagahana</i> with <i>dashmoola kwath</i> & <i>panchwalkal kwatha</i> ⁷	Sitz bath

Grading-

Constipation	Abdominal pain	Secretion	Sphincter tone	Prolapse mass
G 0-No	G 0-No pain	G 0-No	G 0-Normotonic	G 0-1 cm
G 1- Defecation on straining	G 1- Pain but not affecting attendance	G 1- Present only during defecation	G 1- Hypotonic	G 0-1 cm
G 2-Hard stool passage	G 2-Pain reported by school staffs	G 2-Occasional mopping of undergarments		G 2-3 cm
G 3-Defecation only after medication	G 3-Retained at home due to pain	G 3-Continuous mopping of undergarments		G 3-4 cm

	B/T grading	A/T grading
Sphincter tone	1	0
Prolapse mass	3	0
Constipation	3	0
Abdominal pain	2	0
Secretion	3	1

Advice at the time of discharge-

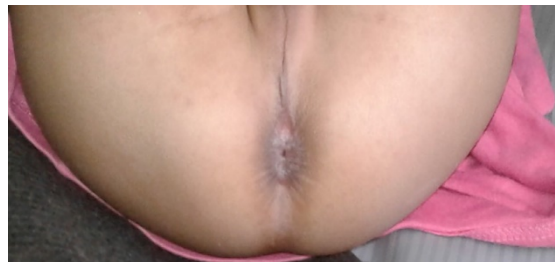

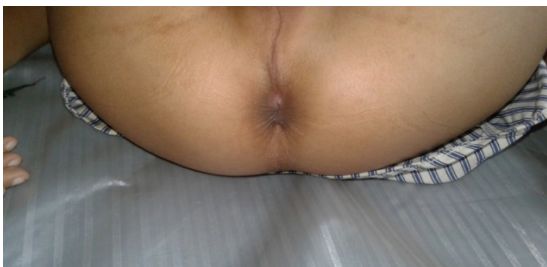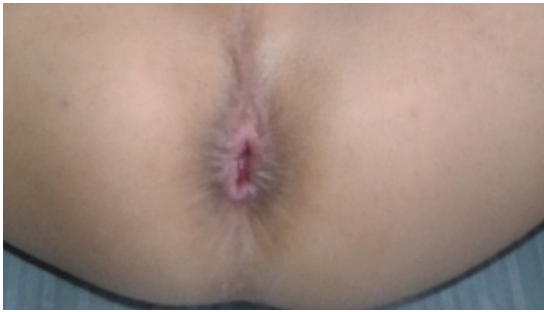
Advice of dietic consideration, *guda pichu* with *mushika taila* twice in a day, morning sitz bath with *dashamool kashaya* and *panchavalkal kashaya*. Orally *Vidangarista* 10 ml bid was con-

tinued for 1 month, *lajjalukalka* 1/2tsp bid was advised and asked for the follow up after 1 month. With this treatment the patient found relief in constipation abdominal pain, rectum was pulled up 1cm, appetite was improved.

Bowel movements were normal no straining was required .Per rectal mass was noticed on

excessive straining. With this the patient was discharged after 10 days.

Pics of case give details of pics



DISCUSSION

Changeri ghrīta helps in *agnideepan* & *pachan*, it improves the appetite. It helps to stop need for straining this helps to reduce the sticky discharge from anus, anal ache & urinary obstruction & also reduce anaemia. *Snehamśha* of *grīta* may reduce the hardness of the stool & hence control the *Apan vata*. *Ghrīta* is also said as *rasayan balya* & *brimhan* .*changeri grīta* has been explained in the *chikitsa* of *prasramsini yonivyapat* w.s.r to uterine prolapse .it specially

gives strengthen the muscle tone so as to maintain its normalcy.

Gūḍa pichu (Rectal suppository) with the *mushika taila pichu* was administered which acts locally so as to reduce ongoing inflammation or fibrotic changes. *Snigdhatā* of tail again provide addition strength to local musculature.

These sneha dravya like oil *grīta* are said to be containing short & long chain fatty acids are absorbed in trough the wall of colon drug absorption through rectal route

Skin-lipid soluble drugs can be applied for slow & prolonged absorption

Sitz bath with the *dashamool* & *panchavalkal kashay*-anti-inflammatory activity might have helped to reduce the edema, *dashamoola kashaya* is said as *balya* hence might improve the sphincter tone. *Lajjalu kalk* is *vatapittahar* & *sheet gunatmak* hence it also control *pitta*, because of its *kashaya rasa* it helps reducing bleeding. Tannins helps in wound healing.

Vidangarista has *krimihar* action as well as *deepan pachan* (digestive and carminant).

Udawartana during initial treatment period will helps in *shroto-shodhana*. **Gandharvahastadi taila** during bed time might help in controlling *vata dosha*, helps to lubricate the stool in rectum & it also act like purgative by this bowels will be cleared well. It helps in *Ama nirharana*, *vi-bandha nasana* as well as *kostha sodhana*.

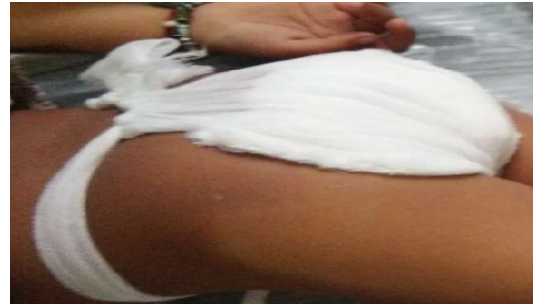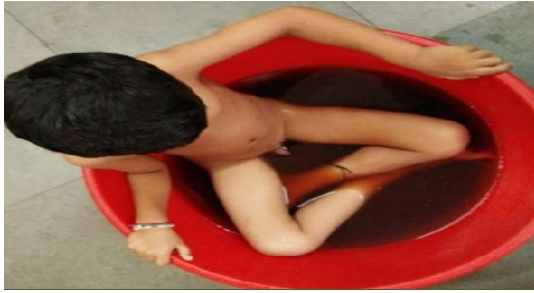CONCLUSION

Rectal Prolapse in paediatric age group is probably because of under developed weak musculature or because of chronic diarrhoea or because of chronic untreated worm infestation. A protocol that includes *nidana parivarjana*, *changeri ghrta*, & *mushika taila pichu* has been found more effective in present case

REFERENCES

1. <http://www.ncbi publication.com/15981062>
2. Robert M.Kliegman Nelson paediatrics 19th edition Vol .2 Chapter 336 P.1361
3. Krishana M Goel,Devendra K Gupta Hutchionson's paediatrics 1st edition Chapter 7 .P129
4. Norman S.williams,Christopher J.K.Bulstrode Bailey & love 26th edition chapter 72 P. 1220
5. G.D.Singhal 2nd Edition Sushruta samhita Nidan sthana Chap. 13 Shloka 61 P.599
6. Edition chaukahambha krishananand academy, Varanasi
7. Bhardwaj U. Sahu.M Role of panchwalkala kwatha in the management of dustha vranas PG dissertation 2010
8. P.V.Sharma Dravyaguna vijanana Reprinted edition 2005 Vol .2 Chapter 5 Chakhambha bharati academy P.503
9. Prof. Siddhi Nandan Mishra Bhaishajya ratnavali Vol 2 Kshudrarogadhikar Shloka 91 P.941
10. Kaviraja Ambika data ,Ayurveda tantra sandipika Sushruta samhita of Su.Chi.20/60-61 14TH edition
11. Review article-Astudy of upyantras to accentuate it's importance in surgical & medical procedure:Jahm vol 4 Aug 2016
12. Prof.Siddhi Nandan Mishra Bhaisajya ratnavali Vol. 1 Chapter 8 Grahani rogadohikar Shloka 559-561 P.302
13. .P.V.Sharma Dravyaguna vijanana Reprinted edition 2005 Vol .2 Chapter 9 P.749
14. Dr.K.M.Nadkarni Indian material medica Reprinted edition 2005 Vol 1 P.799
15. Dr.Rajeev K.Rai Vangasen samhita (Chikitsa sara sangraha) Edition 1 ,Kshudrarogadhikar Shloka 203-207,Varanasi Chowkhmba Sanskrit series office;1983 P.557
16. Dr.Rajeev K.Rai Vangasen samhita (Chikitsa sara sangraha) Edition 1 Grahanyaadhikara Shloka 60-61 ,Varanasi Chowkhmba Sanskrit series office;1983 P.93.

Pics of drug used & pics of procedure



Source of Support: Nil

Conflict Of Interest: None Declared

How to cite this URL: Sachchidanand Et Al: A Case Study On Gudabhrmsha (Partial Rectal Prolapse). International Ayurvedic Medical Journal {online} 2017 {cited December, 2017} Available from: http://www.iamj.in/posts/images/upload/4525_4530.pdf