

ROLE OF AYURVEDIC REMEDIES IN THE MANAGEMENT OF EPIDERMOLYSIS BULLOSA- A CASE REPORT

Chandurkar Vivek. S¹, Ruikar Rasika. Neminath²

¹Prof. & HOD, Kayachikitsa Dept, ²3rd year MD (Kayachikitsa)
S.G.R. Ayurved Mahavidyalaya, Solapur, Maharashtra, India

Email: rasika.ruikar@gmail.com

ABSTRACT

Epidermolysis bullosa is a group of inherited connective tissue diseases that cause blisters in the skin and mucosal membrane. It is a result of a defect in anchoring between the epidermis and dermis, resulting in friction and skin fragility. Its severity ranges from mild to lethal. 'Butterfly Children' is a term often used to describe younger patients (because the skin is said to be as fragile as butterfly's wings), also called 'Cotton wool babies' or 'Crystal skin children'. The present single case study was carried out with the prime aim assessing the effect of Ayurvedic remedies (*Mauktik yukta Kamadudha, Mauktik pishti, Sanshamani Vati.*) on 1.5 years old male patient of Epidermolysis bullosa.

Keywords: Epidermolysis bullosa, *Mauktikyukta kamadudha, mauktik pishti, Sanshaman vati.*

INTRODUCTION

Epidermolysis Bullosa disease is very difficult to cure and it is a challenge for treating the doctor. It is a connective tissue disease that cause blister in the skin and mucosal membrane. It is a result of defect in anchoring between the epidermis and dermis resulting in friction and skin fragility.

The human skin is consisting of two layers outer most layers called epidermis and layer underneath called dermis. There are protein anchors between these two layers that prevent them from moving independently from one another. In people born with Epidermolysis Bullosa the two skin layer lack the protein an-

chors that hold them together resulting in extremely fragile skin even minor mechanical friction like rubbing or pressure or trauma will separate the layer of skin and form blister and pain full sores.

There is no specific treatment in Allopathy medicine to cure the disease only regular dressing for the sores can be done to avoid the infection but Ayurved medicines have lots of to do in this regards.

In this case we had used *Mauktik yukta Kamadudha, Mauktik pishti, Sanshamani Vati.* Patient was advised to avoid bakery products,

Dadhi, Rice, Paryushit aahar, green vegetables, Toor dal and mainly eggs.

After 30 days patient got relief from symptoms.

CASE REPORT:

This is a case of 1.5 year old male patient with *Jalayukt visphot* (Blisters) all over body. Patient presented to us with complaints of *Jalayukt visphot* (Blisters) all over body, *Visphot bhedanottar Sashula* (severe pain) *sadaha* (burning sensation) *Vranotpatti*, *Sparshasahatwa* at that point, *alpa kriyottar shula prachiti*, *Tivra mukhagat sarabh* (Child unable to eat & drink).

The patient had complaints since birth. There is no history of DM & HTN But mother had taken lots of antibiotics during the pregnancy. Patient consulted to skin specialist for the disease and taken medicine for that.

It is matter of pride to present this case that with conventional *ayurvedic* drug remedies patient got relief from symptoms.

GENERAL EXAMINATION:

Mala (Stool): *Malavshatbha kwachit Shabda* (Speech): *Ksheen*,

Mutra (Urine): *Pitvarni, Sadah*

Sparsh (Skin): *Aarktata, Sparshashatwa*

Jeehva (Tongue): *Saama* (coated)

Aakruti: *Karshya* (Thin)

Nadi- (Pulse): 74/min *Bala*:

Kshaya/Hina

OBSERVATION:

Symptoms before treatment	Symptoms after 30 days
<i>Jalyukta Visphot</i> (blisters)	Decreased
<i>Visphot bhedanottera arak-tavarni, Sashool, Sadah Vranouttapatti</i> (Wound formation) <i>all over body</i> .	Decreased
<i>Sprasha-asahatwa</i> (Ten-	Decreased

INVESTIGATION:

In 'Skin Right leg Biopsy' Immuno-fluorecence Mapping showed, Compatible Dystrophic Epidermolysis bullosa

In 'Molecular Genetics' findings, there is homozygous for missence mutation in COL7A1 which is associated with autosomal recessive dystrophic epidermolysis bullosa

VYADHI-GHATAK:

Dosha- Tridosha, (Pittapradhan).

Dushya-Ras, Rakt., Mauns.

Stotas-Rasavahastrotas and Raktavahastrotas.

AIM & OBJECTIVE:

To find out the efficacy of *Ayurvedic* remedies with use of *Mauktikyukta Kamdhudha, Mauktik pishti, Sanshaman Vati* orally in the management of Epidermolysis Bullosa.

MATERIAL AND METHOD:

Mauktikyukta Kamdhudha, 250mg 1tab OD *Ugalun Goghrtasah*, (levigated in Cow's ghee)

Mauktik pishti, 60mg OD, *Ugalun Goghrtasah* (levigated in Cow's ghee) *Sanshaman Vati*, 250mg 1tab OD, *Ugalun Goghrtasah* (levigated in Cow's ghee)

A) TYPE OF STUDY:

Prospective Single Case Study.

B) STUDY CENTRE:

Seth Sakharam Nemchand Jain Ayurved Hospital, Solapur.

derness)	
<i>Alpa kriyo-uttar Shoolvrudhhi</i>	Decreased
<i>Tivra mukhagat sarabh</i> (Child unable to eat & drink).	Decreased

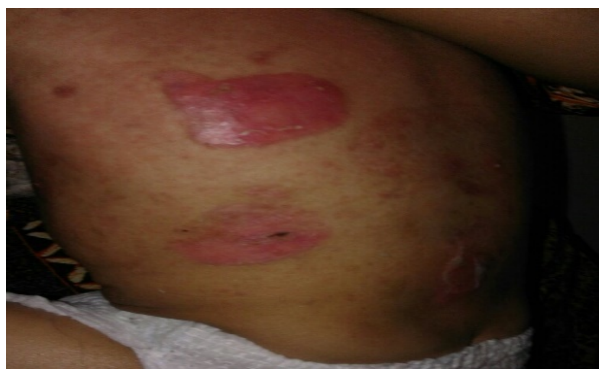The child's mother has taken lots of antibiotics during pregnancy. Child has history of constipation sometime. The symptoms, *Tiva mukhghat sarabh*, *Jalstrava at visphota*, *Sparashashatwa* & *Shoola* is remarkably decreased within 15 days. Other symptoms, *Visphot bhedanottera araktavarni*, *Sashool*, *Sadah Vranouttapatti*, *Alpa kriyo-uttar Shoolvrudhhi* also got relief within 30 days.

DISCUSSION

In this case, patient came with symptoms, *Jalyukta visphot*. (blisters), *Aaraktavarni*, *Sashool*, *Sadah visphotbhednotter Vranouttapatti* (Wound formation) all over body, *Sprasha-asahatwa* (Tenderness), *Alpa kriyo-uttar Shoolvrudhhi*, *Tivra mukhghat sarabh* (Child unable to eat & drink). As per Ayurveda classics, this condition is due to vitiated *pitta* specially *Ushna tiksha guna*, which is causing *Raktidushti* in child. The child's mother has taken lots of antibiotics during pregnancy, which is root cause of vitiation of *pitta* and *raktdushti* in child before birth, while mainly use of lots of EGGs in diet caused vitiation of *pitta* & *raktdushti* in child after birth.

Mauktikukta kamdudha. *Mauktik pishti* are

Before treatment



shamak for ushna tikshna guna of pitta, dahshamak & thus reduces *raktdushti*. *Sanshaman Vati* mainly contains *tikta rasatmaka guduchi choorna*, which will act as *pittashamak, raktshuddhikara* in this patient.

RESULTS

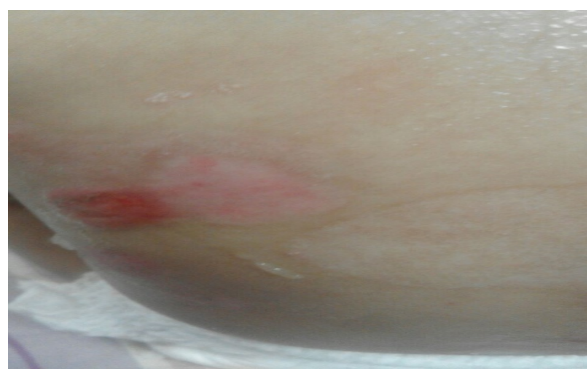
At the end of 30days,

The *Jalyukta Visphot*. (blisters), *Aaraktavarni*, *Sashool*, *Sadah visphotbhednotter Vranouttapatti* all over body, *Sprasha-asahatwa*, *Alpa kriyo-uttar Shoolvrudhhi* symptoms got relieved by Ayurvedic remedies with use of *Mauktikyukta Kamdhudha*, *Mauktik pishti*, *Sanshaman Vati*.

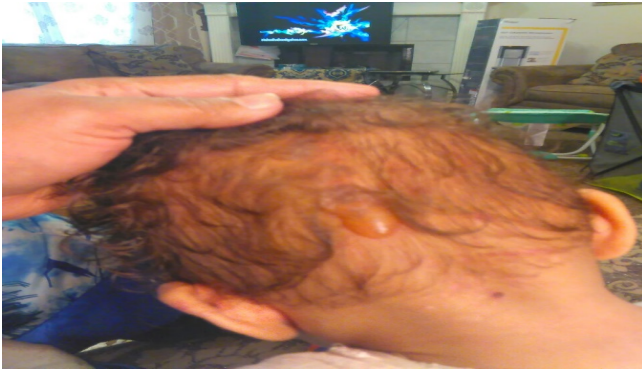REFERENCES

1. A. Kumar Santosh, Volume 2, Section 3, Dermatological Problems, Manual of New-born Care, 2nd edition-2011, Published by Divyesh Arvind Kothari for Paras Medical Publisher, Hyderabad.
2. Shree Krushnanandaji Maharaj, Writer, Pratham khanda, Bhasma Prakaran and Khalviya Rasayan Prakaran, Rastantrasar and Sidhhaprayogsangrah, 20th edition-2011, Published by Krushnagopal Ayurved Bhavan, Rajasthan.

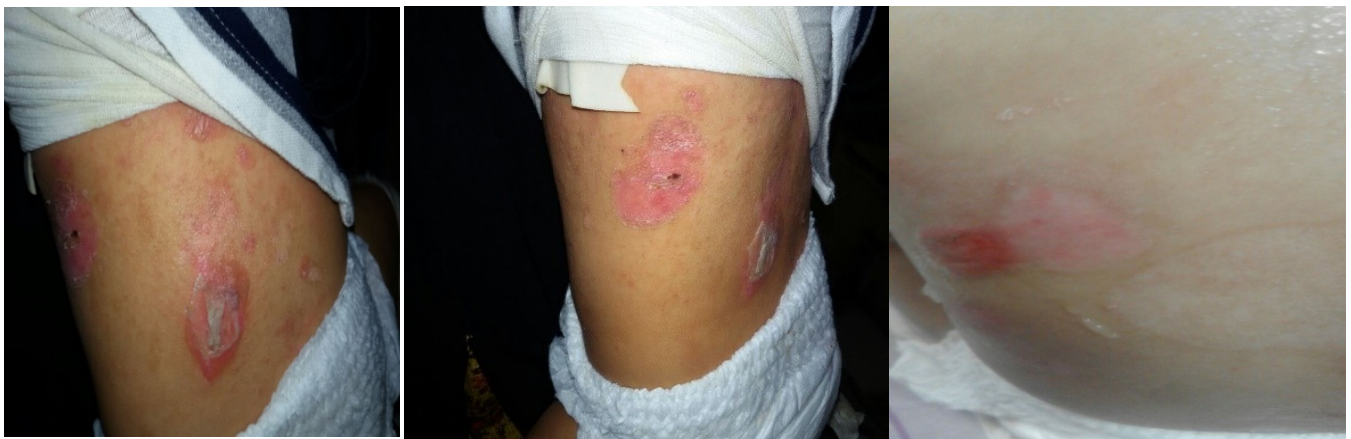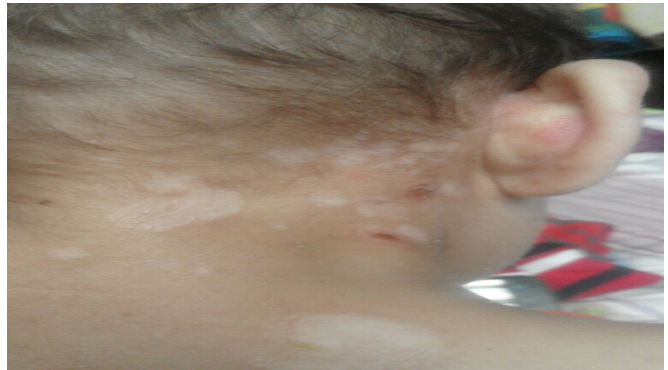After treatment-



Before treatment



After treatment-



Source of Support: Nil

Conflict Of Interest: None Declared

How to cite this URL: Chandurkarvivek, S & Ruikarrasika, Neminath: Role Of Ayurvedic Remedies In The Manangement Of Epidermolysis Bullosa- A Case Report. International Ayurvedic Medical Journal {online} 2017 {cited March, 2017} Available from: http://www.iamj.in/posts/images/upload/994_997.pdf