

MANAGEMENT OF RECURRENT COMPLICATED FISTULA-IN-ANO WITH PARTIAL FISTULOTOMY AND KSHARASUTRA – A CASE REPORT

Shalini U.A.¹, Siddayya Aradhyamath²

¹3rd year PG Scholar, ²Professor and HOD;

Dept of PG studies in Shalya Tantra. Dept of PG Studies in Shalya Tantra. JSS Ayurvedic Medical College and Hospital, Mysore, Karnataka, India

Email: drshaliniua@gmail.com

ABSTRACT

A fistula-in-ano is an abnormal hollow tract or cavity that is lined with granulation tissue and that connects a primary opening inside the anal canal to a secondary tract, which may be multiple and can extend from the same primary opening¹. In *Ayurveda bhagandara* is one among the *mahagadha* (troublesome diseases) which are difficult to manage and recurrence after surgery is very high. This case history demonstrates the recurrence of fistula in ano after multiple surgeries and its successful ayurvedic management in healing of the fistulous tract. A 24 - year old male patient was diagnosed to have fistula in ano since 2 years, Patient complained of constipation with difficulty in passing stool; associated with pus discharge, pain. He presented with a history of fever since 3 days. MRI – fistulogram report suggestive of a complicated fistula. Patient past history revealed that he had undergone 6 anorectal surgeries, among them one for fissure in ano, two times for haemorrhoids- (Haemorrhoidectomy), 3 surgeries for fistula in ano, in a span of 2 years. He underwent fistulotomy 3 times but had recurrence of the fistula. Based on these factors patient was treated with Apamarga Ksharasutra procedure as a shastra chikitsa, wound dressing with jathyadi taila, and followed by Abhayarishta, Drakshasava, gandhaka rasayana and anuloma DS as shamana chikitsa. After the 3 months of therapy fistulous tract was completely healed. In this case Apamarga Ksharasutra helped in simultaneous cutting and healing of the fistulous tract without doing sphincter damage. Further, administered drugs acted as laxative, anti- inflammatory and wound healing promoters.

Keywords: *Mahagadha*, complicated fistula, *ksharasutra*, *bhagandara*.

INTRODUCTION

Most fistulas are thought to arise as a result of cryptoglandular infection with resultant perirectal abscess. The abscess represents the acute inflammatory event, whereas the fistula is representative of the chronic process. Symptoms generally affect quality of life significantly and they range from minor dis-

comfort and drainage with resultant hygienic problems to sepsis¹.

According to Acharya Sushruta, there will be formation of a pidaka, and it presents within 2 fingers periphery of guda and it will be deeply rooted and as-

sociated with pain and fever. When pidaka bursts open, it is called bhagandara.

Anatomy:-The external sphincter muscle is a striated muscle under voluntary control by three components: submucosal, superficial, and deep muscle. Its deep segment is continuous with the puborectalis and forms the anorectal ring, which is palpable upon digital examination.

The internal sphincter muscle is a smooth muscle under autonomic control and is an extension of the circular muscle of the rectum. In simple cases, the Goodsall rule can help anticipate the anatomy of a fistula-in-ano. This rule states that fistulas with an external opening anterior to a plane passing transversely through the center of the anus will follow a straight radial course to the dentate line. Fistulas with their openings posterior to this line will follow a curved course to the posterior midline. Exceptions to this rule are external openings lying more than 3 cm from the anal verge. These almost always originate as a primary or secondary tract from the posterior midline, consistent with a previous horseshoe abscess. [2, 3]

Etiology:- In the vast majority of cases, fistula-in-ano is caused by a previous anorectal abscess. Typically, there are eight to 10 anal crypt glands at the level of the dentate line in the anal canal, arranged circumferentially. These glands penetrate the internal sphincter and end in the intersphincteric plane. They provide a path by which infecting organisms can reach the intramuscular spaces. The cryptoglandular hypothesis states that an infection begins in the anal canal glands and progresses into the muscular wall of the anal sphincters to cause an anorectal abscess.

After surgical or spontaneous drainage in the perianal skin, a granulation tissue-lined tract is occasionally left behind, causing recurrent symptoms. Multiple series have shown that formation of a fistula tract after anorectal abscess occurs in 7-40% of cases. [4, 5]

Methods:-

A 24 year old male patient was diagnosed to have fistula in ano since 2 years, reported to OPD of Shalya tantra department in the month of December 2017 at JSS Ayurvedic medical college and hospital, Mysuru.

Patient was complaining of difficulty in passing the stool, constipation, pus discharge, pain and history of fever since 3 days. On examination, indurations were present in and around the anal canal. Thorough examination was not done due the loaded rectum, indurations and tenderness. MRI(Fig-1) – fistulogram report reveals Bilateral intersphincteric abscesses connected by a posterior horseshoe abscess with bilateral supralelevator extension and a blind ending transphincteric secondary branch on right side-complicated fistula (St. James University Hospital Classification Grade V).

Past history:- He had undergone 6 anorectal surgeries, among them one for fissure in ano, two times for haemorrhoids- Haemorrhoidectomy, 3 surgeries for fistula in ano, in a span of 2 years. He underwent fistulotomy 3 times but had recurrence of the fistula. Not a known case of Diabetes mellitus, Tuberculosis, Crohn's disease, Hypertension.

Patient posted for surgery after taking physician's fitness. Patient's informed consent was taken; all the pre-operative measures were followed.

Under spinal anaesthesia, with all aseptic precautions, patient was laid in lithotomy position. Part was painted with betadine and draping was done. On digital examination, abscess cavities were traced. On draining the pus from all abscess cavities, a bigger abscess cavity was present at 6' o clock position within the anal canal. It was drained completely and the abscess cavity was partially excised on both the sides for posterior horseshoe abscesses. With thorough probing, fistulous tracts were "identified", and primary threading was done to the fistulous tracts. Primary threading was done to the fistulous tracts after finding their internal openings. Thorough washing and cleaning of the wound was done. Since it was a large cavity it was packed using jathyadi taila

soaked gauze. Daily dressing was done with Jathyadi taila. Primary thread was replaced with the Apamarga kshara sutra in the first sitting and every seven days once, a new kshara sutra was replaced by rail road technique till it gradually divided the enclosed muscle.

After the surgical procedure, wound dressing was done with Jathyadi taila. False bridging of the

wound edges was prevented with keeping ribbon gauze soaked with jathyadi taila.

Shamanoushadis (Oral medications) given:-

Tab. Gandhaka Rassayana 2-0-2 After food

Tab. Biogest 1-0-1 After food

Tab. Anuloma DS 0-0-1 After food

Tab. Kamadudha moukthika 1-1-1 Before food

Abhayarishta 15 ml-0-15ml After food

Drakshasava 15ml-0-15ml. After food.

Fig 1:- Report of MRI

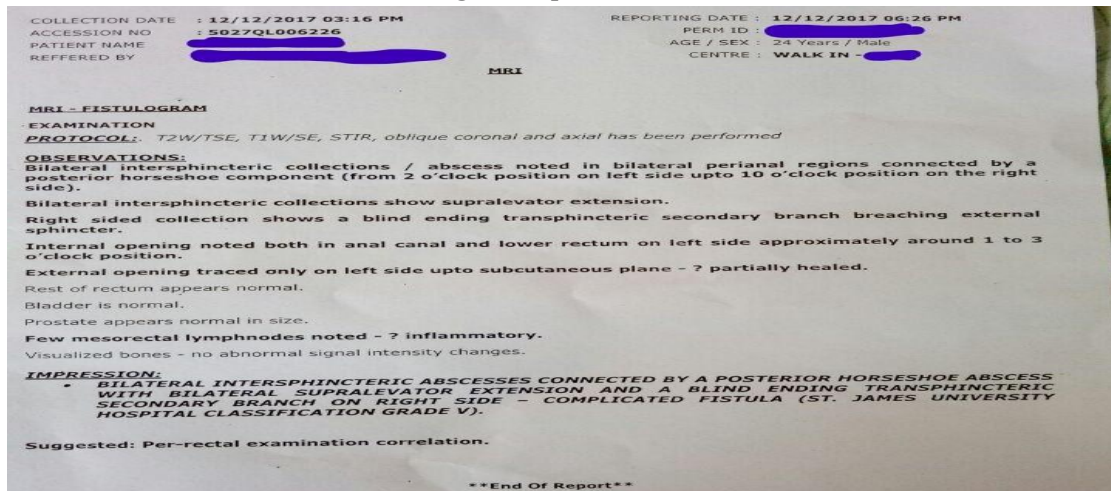


Fig 2: On the operative day- after the surgical procedure - Partial fistulotomy along with Ksharasutra therapy

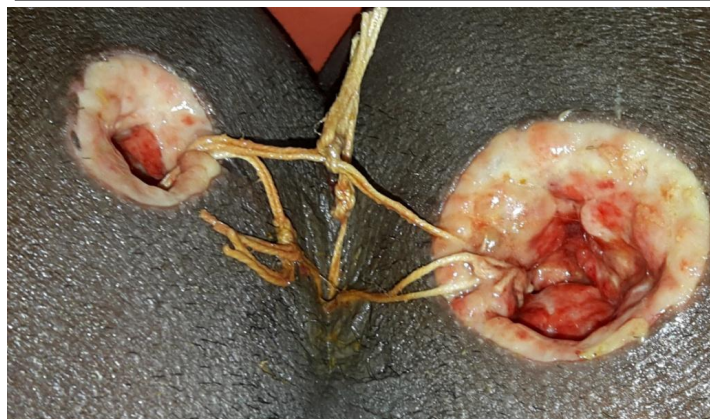

Fig 3 Wound depths was assessed by inserting the fingers into the cavity and the wound was thoroughly cleaned.

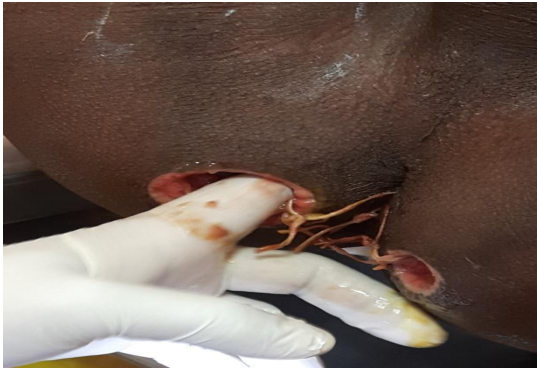

Fig 4: Kshara sutra length was measured to check the probable duration of fistulous tract healing.

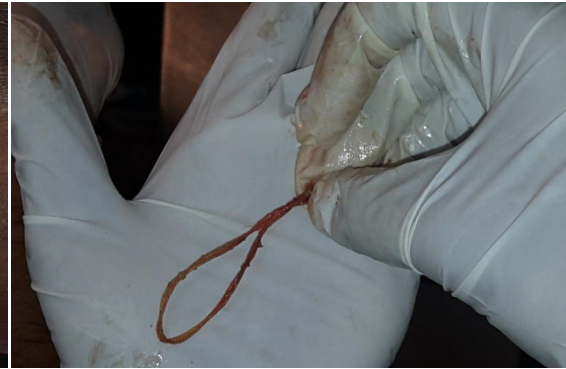

Fig 5: Wound after 15 days. Wound is healing, Healthy granulation tissue present. Sero “sanguineous discharge” was present.

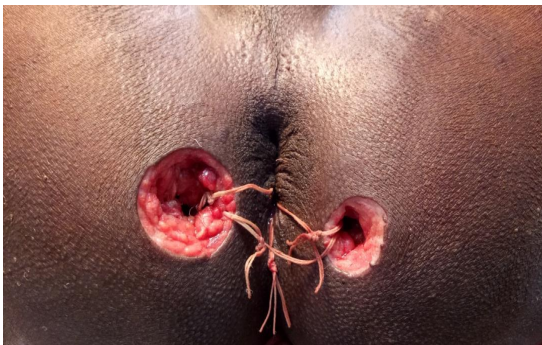


Fig 6: wound on 30th day. Wound healed from inside. No pus discharge

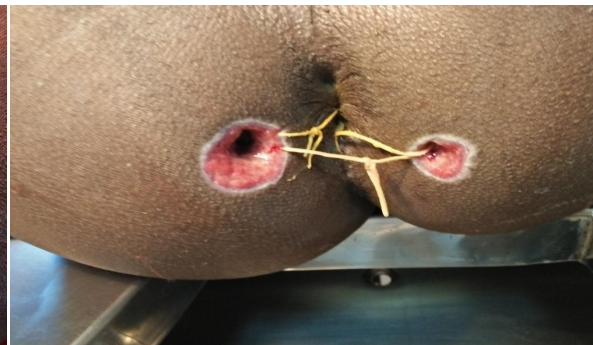


Fig 7: Wound on 40th day. To prevent the wound closure from apex Jathyadi taila soaked gauze was placed in the cavity. Wound is healthy.

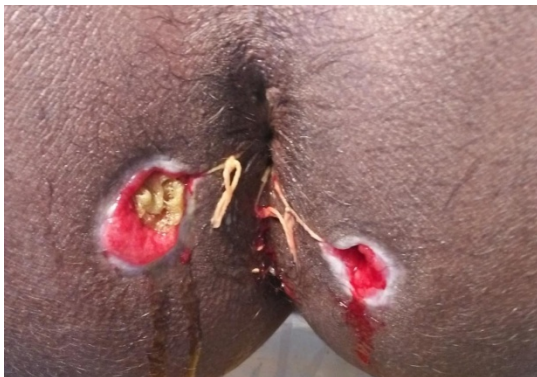
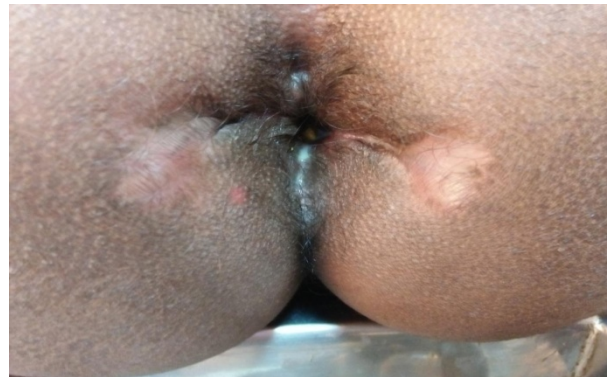
Fig 8: During the follow up period. On the 80th day, Wound healed completely. Scar marks present. No signs or symptoms present.



Wound completely healed by the 60th day. Kshara sutra was removed on 56th day and tract healed on its own later. But follow up was done till date (5 months) and will be doing for a year to check for incontinence and for other symptoms.

DISCUSSION

Ischiorectal abscesses are the second most common type of abscesses. These abscesses form when sup-puration transverses the external anal sphincter into the ischiorectal space. An ischiorectal abscess may transverse the deep postnatal space into the contra lateral side, forming horseshoe fistula.

Common complications after fistula surgery are recurrence of fistula or abscess, incontinency, anal stenosis, delayed wound healing.

Treatment of fistula in ano remains challenging,⁶ no definitive medical therapy is available for this condition. Surgery is the treatment of choice, with the goals of draining infection, eradicating the fistulous tract and avoiding persistent or recurrent disease while preserving anal sphincter function.

Partial laying open technique along with kshara sutra therapy helped in faster healing of the tract.

Daily dressing with Jathyadi taila and keeping the soaked gauze inside the wound cavity prevented the bridging and made the wound to heal from inside.

Mode of action of Ksharasutra⁷:-

Debridement of unhealthy granulation tissues.

The presence of Kshara sutra in the fistulous tract does not allow the cavity to close down from either ends and there is a continuous drainage of pus along the kshara sutra itself.

The Ksharasutra gradually cuts and heals spontaneously along the fistulous tract from apex to the periphery. It will not allow any pus pockets to stay back. It allows epithelialisation of fistulous tract, thereby preventing secondary closure and facilitating the drainage of abscesses.

The Kshara applied on the thread has the property of anti inflammatory and chemical curetting, therefore it chemically cures out the fistulous tract and

sloughs out the epithelial lining, allowing the tract to cut and heal simultaneously.

CONCLUSION

Ano rectal abscess with horseshoe fistula is a complicated fistula. This leads to a lot of difficulty in finding the correct openings of the tracts and to get right treatment for fistula. This case was managed with Ksharasutra therapy, a minimal invasive technique, with less rest, doing routine work throughout the course of treatment, without incontinence and complete healing of the wound.

REFERENCES

1. <https://emedicine.medscape.com/article/190234-overview> Updated: Jun 07, 2017
2. Rosen L. Anorectal abscess-fistulae. *Surg Clin North Am.* 1994 Dec. 74(6):1293-308. [Medline].
3. Ross ST. Fistula in ano. *Surg Clin North Am.* 1988 Dec. 68(6):1417-26. [Medline].
4. Hancock BD. ABC of colorectal diseases. Anal fissures and fistulas. *BMJ.* 1992 Apr 4. 304(6831):904-7. [Medline].
5. Hamalainen KP, Sainio AP. Incidence of fistulas after drainage of acute anorectal abscesses. *Dis Colon Rectum.* 1998 Nov. 41(11):1357-61; discussion 1361-2. [Medline].
6. Phillips J, Lees N, Arnall F. Current management of fistula-in-ano. *Br J Hosp Med(Lond).* 2015 mar. 76 (3): 142, 144-7. [Medline].
7. Nadkarni AK. Nadkarni's Indian Materia Medica, 2nd Edition, Vol. I, Dhootapapeshwar Prakashan Ltd. Panwel, India; 1954. P. 524.

Source of Support: Nil

Conflict Of Interest: None Declared

How to cite this URL: Shalini U.A. & Siddayya Aradhyamath: Management Of Recurrent Complicated Fistula-In-Ano With Partial Fistulotomy And Ksharasutra – A Case Report. International Ayurvedic Medical Journal {online} 2018 {cited May, 2018} Available from: http://www.iamj.in/posts/images/upload/1182_1186.pdf