

MANAGEMENT OF UNHEALED VARIETY OF PILONIDAL SINUS - A CASE STUDY

Divyashree. P.V¹, Siddayya Aradhyamath²

¹PG Scholar, ²Professor HOD.

Dept. of PG studies in *Shalya Tantra*, JSS Ayurveda Medical College, Mysuru, Karnataka, India

Email: pvdivyashree@gmail.com

ABSTRACT

Pilonidal sinus is a very common disease and its most frequent location is in the pre-sacral area. It is common in males and mostly affects hairy men. Its recurrence rate is 30-40% there are two types primary & secondary Pilonidal sinus. It also occurs in other parts of the body like in between fingers, axilla, eyelid are extremely rare. Here is the case study of a boy aged 17 years old college student complaints of wound over the pre-sacral region. Wound was a result of incomplete excised Pilonidal sinus. Patient underwent surgery for pilonidal sinus 4 months back. The wound did not heal since after surgery so came to our OPD with pus discharge from wound associated with pain. In OPD on wound examination and on probing sinuses traced. So patient admitted in our hospital, after admission necessary blood routine investigation done. Under spinal anaesthesia probing done within the wound, 2 sinuses were present for that primary threading done. On third post- op day, primary threading was replaced by *Apamarga Kshara sutra*. *Ksharasutra* was replaced on every 7th day for next 4 consecutive weeks & *Jatyadi taila* dressing daily done. Wound healed completely in 60 days.

Keywords: Pilonidal sinus, *Nadivrana*, *Kshara sutra*.

INTRODUCTION

Pilonidal sinus Pilus means hair, Nidus means Nest. It is Epithelium lined tract, situated short distance behind the anus, containing hairs and unhealthy diseased granulation tissue. It is due to penetration of hairs through the skin into subcutaneous tissue. It forms granuloma/unhealthy granulation tissue in deeper plane. It is common in Hair dressers, Jeep drivers. It is common in 20-30yrs of age. It is common in males and hairy men. Pilonidal sinus can be correlated to *Nadi Vrana*. "*Tasyaatimatragamand gati ityatscha nadiva yadvahati tena mata tu nadi*".¹ It means, because of *Puya* (Pus) moving inside

greatly it is known as *Gati* & since the spread is through a tube it is called *Nadi*. Here is the case of a variant of pilonidal sinus its extension upto left medial part of thigh. Treated with *Apamarga kshara sutra* gave best result.

PATHOLOGY:

Hair in the cleft region →penetrates the skin-dermatitis→pustule formation→Sinus formation→hair gets sucked into the sinus by negative pressure in the area →further irritation & granulation

tissue formation→pus forms→multiple discharging sinus².

METHODS:

A 17 year old boy came to Shalya OPD, JSS Ayurveda Hospital, Mysuru, with a wound over presacral region it was associated with pus discharge & pain. The present wound was a result of incomplete excised pilonidal sinus. Patient had undergone surgery for Pilonidal sinus 4 months back in some other hospital. After surgery patient went for regular dressing but wound did not heal completely. Patient presented with persistent pus discharge from wound:-

On examination of wound:-

On Inspection: Site of wound was Presacral region, Number-1, size-3x2cms, Floor-unhealthy granulation tissue, Colour-pale whitish, profuse pus discharge. On probing 2 sinuses traced, one sinus present at 2cm away and anterior to wound (fig 2). Another sinus 5cms away and posterior to wound connecting medial part of left thigh region (fig 3)

Pre - Operative procedure –Patient consent taken, part preparation done.

Operative procedure –Under Spinal Anaesthesia patient put in Jack knife position part painted with aseptic precautions & draped. On probing within a wound sinus track (Fig 2) found at 2cms above the wound in midline, a nick given at that point and fistula is made. A plain Barbour thread no.20 is tied between intercommunicating fistulous tracks. Another sinus (Fig 3) found at 5cms below & left lateral to wound, which connects to left thigh. Another nick is given and fistulous track made these second sinus tract intercommunication also tied with plain Barbour thread no.20 as primary threading. Wound was cleaned with Betadine and Hydrogen peroxide, once again thoroughly washed with normal saline. *Jatyadi Taila* was dressing done.

Post- operative care – On third post-operative day both primary threading changed with *Apamarga ksharasutra*. Both fistulous tract are cleaned and dressed with *Jatyadi taila* everyday till wound

healed. For 4 Consecutive weeks weekly once *Apamarga kshara sutra* was changed. Patient was advised for maintenance of hygiene at operated site and removal of hairs around presacral region at regular intervals.

RESULTS

First two weeks there was profuse pus discharge from wound and fistulous track. From 2nd week onwards, healthy granulation tissue was seen over floor of wound. Every week there was cutting of 1cm of fistulous track. After 3 weeks of surgery anteriorly present track thread removed completely. In next two weeks posteriorly present thread removed.

The chronic wound which was not healed since 160 days got completely healed in 60 days.

DISCUSSION

In contemporary surgery treatment for Pilonidal sinus is excision through ‘Z’ plasty technique or some other techniques are used. In this case as it was the unhealed Pilonidal sinus or incomplete excision of sinus track during surgery. Here *Acharya Sushruta* concept of *Nadi Vrana Chikitsa* is used “*Yato Yato Gatim Vidyatutsango Yatra Yatra cha, Tatra Tatra Vranam Kuryadtha Doshho na Tistati*³”. This *shloka* conveys after determining the route of sinus and places of *utsanga*, *vrana* (incision) can be made so that doshas(pus, blood) do not remain inside the gati. Pilonidal sinus track contain dead granulation tissue and Pus discharge. *Nadi vrana* definition because of Pus moving inside greatly it is known as *Gati* & since the spreading is through a tube is called as *Nadi*.

Any foreign body (*shalya*) lost within the tissues (*dhatu*s) produces a *Nadi* quickly which exudes a warm liquid, frothy, churned up, clear or mixed suddenly and accompanied with pain. In these *Kesha* (hair) and *puya* are the *shalya*'s. So, this Pilonidal sinus can be compared with *Shalyaja Nadivrana*.

For treatment of *Nadivrana* in *Krishna, durbala beeru, marmasrita nadi*, *Ksharasutra*⁴ is used. *Acharya Sushruta* has also mentioned technique of tying the *ksharasutra* in *Nadi Vrana*. It follows as

these *Nadi* is probed with a *Eshani* (probe), then introduce the needle having *Ksharasutra* till the end of *Nadi* is reached, the needle is then lifted up, the end of the thread is pulled out and tight knot tied⁵.

Kshara sutra is made of *kshara*, *Snuhi ksheera*, *Haridra choorna*.

Kshara has the property of *Chedana*, *Bhedana*, *Lekhana*, *Tridoshagna*. So, it is *pradanatama* among *shastra* and *anushastra*. In Pilonidal sinus case the track will be lined with unhealthy track and Pus discharge, *Kshara* does *chedana* of unhealthy tissue in track and *Lekhana* of Pus.

Snuhi ksheera act as a binding agent while preparing *Kshara sutra* and does *Lekhana karma*. *Haridra* acts as an antiseptic and *Vrana ropana* property.

Jatyadi taila is used for dressing as *taila* as the property of *vrana shodana* and *vrana ropana*.

Because of above said property of *Kshara sutra*, in this case which is an unhealed case of Pilonidal sinus, as patient is in *bala avastha* *Ksharasutra* procedure adopted.

Oral medications

- Tablet *Triphala guggulu* 1 T.I.D,
- Tablet *Gandhaka rasayana* 1B.D. given after food for 30days.
- *Amalaki rasayana* 5gms B.D. after food for 60 days.

Before treatment

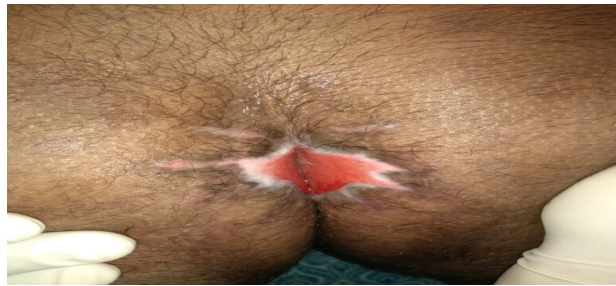


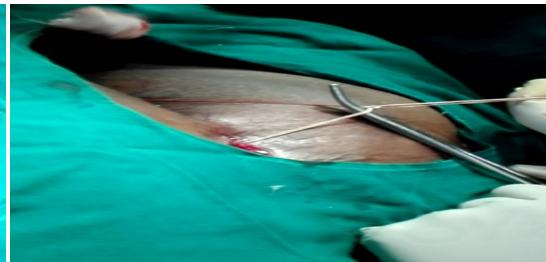
Fig.1:

During treatment

Fig.2:

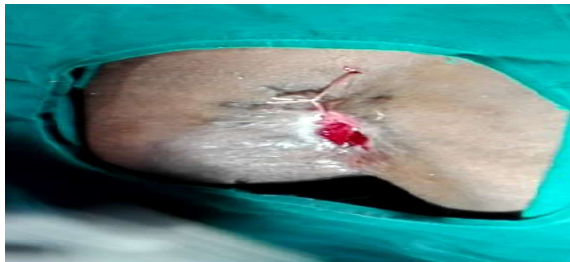

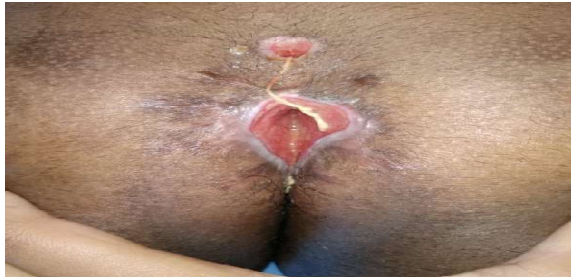Fig.3:



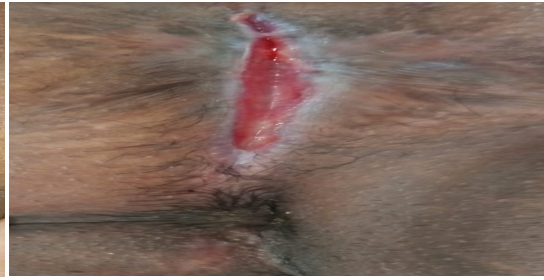
After Treatment

Fig.4:



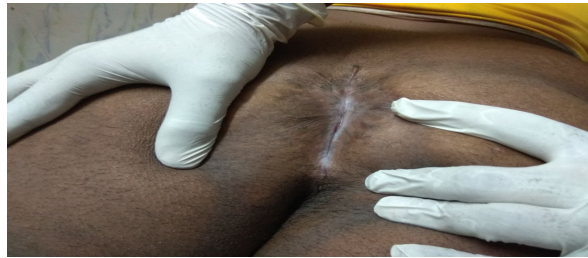After treatment-20 days

Fig.5



After treatment-40days

Fig.6



After treatment-60days

CONCLUSION

Even though there may be many procedure to treat Pilonidal sinus, but *Kshara sutra* stands first. It may be primary, secondary Pilonidal sinus or recurrent one, *Kshara sutra* holds good. Here in this case, patient was very young suffered with lot of pain and discomfort after surgery due to unhealed wound with pain and pus. By tracing proper *gati* of *nadi* and ligation of *ksharasutra* relived pain of patient in much more better way and in shorter duration. As said *Kshara* stand *pradhanatama* among *shastra* and *anusashastra*.

REFERENCES

1. *Sushruta, Sushrutha samhita, Nibandasangraha* commentary of *Dalhanacharya* edited by *AcharyaYadavji Trikamji*, Choukhamba surabharati prakashan, Varanasi, reprint on 2017, *Nidana sthana*, 10th chapter, 10th shloka
2. Bhat M Sriram; SRB's Manual of Surgery; 5th edition; New Delhi; Jaypee Brother Medical Publishers(P)Ltd; 2016 ; pg no 967.
3. *Sushruta, Sushrutha samhita, Nibandasangraha* commentary of *sri Dalhanacharya* edited by *AcharyaYadavji Trikamji*, Choukhamba surabharati prakashan, Varanasi, reprint on 2017, *Sutra sthana*, 5th chapter, 12th shloka.

4. *Sushruta, Sushrutha samhita, Nibandasangraha* commentary of *sri Dalhanacharya* edited by *AcharyaYadavji Trikamji*, Choukhamba surabharati prakashan, Varanasi, reprint on 2017, *Chikitsa sthana*, 17th chapter, 28th shloka .
5. *Sushruta, Sushrutha Dalhanacharya samhita, Nibandasangraha* commentary of *sri Dalhanacharya* edited by *AcharyaYadavji Trikamji*, Choukhamba surabharati prakashan, Varanasi, reprint on 2017, *Chikitsa sthana*, 17th chapter, 33rd shloka.
6. *Sushruta, Sushrutha samhita, Nibandasangraha* commentary of *sri Dalhanacharya* edited by *AcharyaYadavji Trikamji*, Choukhamba surabharati prakashan, Varanasi, reprint on 2017, *Sutra sthana*, 11th chapter, 3rd shloka.

Source of Support: Nil

Conflict Of Interest: None Declared

How to cite this URL: Divyashree. P.V & Siddaya Aradhyamath: Management Of Unhealed Variety Of Pilonidal Sinus - A Case Study. International Ayurvedic Medical Journal {online} 2018 {cited August, 2018} Available from: http://www.iamj.in/posts/images/upload/1847_1850.pdf