

MANAGEMENT OF DIABETIC RETINOPATHY WITH AYURVEDIC TREATMENT PROTOCOL - CASE REPORTS

Jadhav N.M.¹, Auti Swapnil²

¹Research Officer (Ayu.), CARICD, CCRAS, New Delhi, India;

²Associate professor, Faculty of Indian medicine, SGT University, Gurgaon, Haryana, India

Email: nandini.punarvasu84@gmail.com

ABSTRACT

Conventional management of DR involves prevention of hyperglycemia and management of ailments like vitreous haemorrhage, neovascularisation etc. panretinal photocoagulation is though effective but tedious procedure hence patients often look for some better alternative. Selected treatment protocol involving *Doorva Swarasa Nasya, Mukhalepa & Pana* of certain Ayurvedic drugs have shown promising results in 3 cases reported in prevention and resolving of vitreous haemorrhage, & neovascularisation.

Keywords: *Nasya, Mukhalepa, Pana*, diabetic retinopathy, vitreous haemorrhage

INTRODUCTION

Concept of DR in Ayurveda: Diabetic retinopathy occurs in long standing diabetic patients. Thus indicates result of complication of *Madhumeha*. Clinical findings in ophthalmic examination include microaneurysms, macular edema, neovascularisation, vitreous haemorrhage (VH) and blurring of vision. Based on the progression of the DR, pathogenesis in Ayurvedic parlance can be explained as below.

Diabetic retinopathy basically a *Dristipatalagata Roga* is mainly attributed to *Sira Srotasabhisyandam* and *Raktavaha Sroto Dusti* due to a variety of *Achakshyushya Ahara* and *Vihara Karana* especially *Prameha Nidana*. *Nidana* of endogenic eye diseases are mainly *Achakshyushya* factors which vitiates *Pitta*. The vitiated *Pitta* in turn vitiates the *Pittavaha Srotas*. Due to interconnection of *Pitta* and *Rakta*, which shares *Ashrya Ashrayee Bhava*, the *Raktavaha*

Srotas also gets vitiated due to *Pitta* vitiation. As the *Nidana* factors are *Achakshyushya*, the vitiated *Pitta* and *Rakta* have an affinity towards penetrating the eyes. Hence, the vitiated *Dosha* move towards the eyes through *Jatroordhwa Srotas* and finally gets confined to the eyes and there is a stage when the *Sirasrothas* are deeply involved which is known as *Sira Abhisyanda*¹ The whole pathology of diabetic retinopathy which starts with *Sroto dusti* of *Raktavaha Srotas* manifested as microangiopathy in the form of *Atipravritti*, *Sanga* and *Granthi* as haemorrhages, exudates and venous beading in diabetic retinopathy respectively.

Sense organs perceive their objects with the help of *Pranavayu*. *Vyanavayu* is responsible for *Gati* or conduction. In case of diabetic retinopathy vascular disorder may arise due to *Pranavritta Vyana*. This

initially causes retinal ischemia and followed with successive cascade of retinopathic changes like neovascularisation, cotton wool spots and intra retinal micro-vascular abnormalities (IRMA). Early break down of blood retinal barrier (BRB), hard exudates formation and macular edema are other symptoms to follow.

Another pathology that occurs in DR is *Rakatvrita-Vata* symptoms of which are: *Twakmamsa Antara-jadaha* and *Raktayukta Sotha Mandala*.² These type of symptoms can be correlated with general neuropathy; *Raktayukta Sotha Mandala* can be correlated with splinter haemorrhages and IRMA as well retinal edema. Most of the etiological factors responsible for *Raktaja Vyadhi* have similarity with *Madhumeha* and *Prameha* etiological factors. *Akshiragam-Tamasyatidarshanam* and *Raktapitta* are described as *Raktaja Vyadhi* in Charak Samhita. These can be correlated with vision defects in diabetics due to microvascular complications. In diabetic retinopathy though initially *Raktakshya* and ischemia occur but

later on blood circulation increases, which lead to haemorrhages and exudative features.

Another important event in DR is *Dhatukshaya*. *Sirasaithilya* is one of the major signs of *Raktakshaya* as per Sushruta.³ Loss of pericytes and formation of micro aneurysms are earliest signs of Diabetic Retinopathy. These can be correlated with *Sirasaithilya* due to *Raktakshaya*. First *Patala* consists of *rasa* and *Rakta Dhatu*, so manifestation of the disease is in the form of micro aneurysms and less severe in nature, which are very similar to background Diabetic retinopathy or mild NPDR and symptoms of 1st *Patalagata Timira* appears in this stage. If *Raktakshaya* persists for long time, it may leads to hypoxia related neovascularisation in Diabetic retina.

Based on Samprapti of the DR *Vata-Pitta Dushti* in *Pittasthana* & *Amajanya Kledapradhana Dhatu-shaithilya* are main events. Thus treatment principal involves *Amapachana*, *Kledanirharana*, *Vata-pitta Shamana* & *Raktaprasadana*. Hence, treatment protocol is decided as follows,

Table 1: Details of interventions:

Drug	Dose
<i>Durva Swaras Nasya</i>	4 drops in each nostril daily
<i>Kaishor guggulu</i>	500 mg TDS
<i>Mukhalepa</i> with <i>Triphala</i> , <i>lodhra</i> , <i>Yashtimadhu</i> , <i>Darvi</i> , <i>Vidanga</i>	Q.S. with Warm water
<i>Phanta</i> prepared with <i>Triphala</i> , <i>lodhra</i> , <i>Yashtimadhu</i> , <i>Darvi</i> , <i>Vidanga</i> (1gm each)	100 ml <i>Phanta</i> prepared with 5gm <i>Churna</i> BD before lunch and dinner.

As, DR is a chronic & *Yapya* disease duration of the treatment was not fixed & same treatment protocol is adopted throughout the treatment period but follow ups were taken at regular intervals.

CASE 1:

Patient

A 67-year-old female.

Chief complaint

Decreased vision in the left eye with floaters.

History of present illness

This patient was being followed-up by an ophthalmologist for vitreous haemorrhage due to bilateral DR. The DR had previously been treated with bilateral panretinal photocoagulation (PRP). In May 2014, injection avastin was given bilaterally for vit-

reous haemorrhage due to PDR. Still vitreous haemorrhage continues to occur at an interval of 6 months as per the patient. In jan 2015 after taking injection avastin patient visited Shalakya O.P.D at Dr. D.Y. Patil college of Ayurved and research centre to prevent and treat the recurrent vitreous haemorrhage due to PDR.

Past medical history

The patient had been diagnosed with type 2 diabetes in 1980. She began taking oral hypoglycemic drugs, and later on shifted on to insulin along with oral

drugs due to poor glycemic control. She was also taking antihypertensive drugs for treatment of hypertension since last 6 years. Ongoing medications while starting Ayurvedic drugs were as follows.

Aspirin 75 mg OD
 Telma 40 BD
 Insulin 10U BD
 Ozomet VG 1 BD

Family history

None of the patient’s relatives had a history of DR. Her father had diabetes, and her mother had hypertension.

Findings on initial ocular examination

Upon initial ocular examination on 22 jan 2015 the patient’s visual acuity (VA) was 6/24(p) bilaterally. intraocular pressure (IOP) was 14 mmHg in both eyes. The anterior eye segments showed no abnormalities. On examination intraocular lens was observed bilaterally. Fundoscopy of the right eye showed dot and blot haemorrhage & neovascularisation elsewhere (NVE) in all quadrants. Vitreous haemorrhage in the patient’s left eye obscured the optic disc and the fundus could not be examined in detail.

Findings on general physical examination

Blood-test results were as follows: FBS 123, PPBS 212, total cholesterol 113 mg/dL; and triglycerides 91 mg/dL.

Table 2: Follow-up course

Date	Visual acuity		Ph	
	Rt eye	Lt eye	Rt eye	Lt eye
22-01-2015	6/24 (p)	6/24 (p)	6/18	6/18
05-03-2015	6/18(p)	6/18(p)	6/12	6/12
13-06-2015	6/12	6/9	6/9	6/9
7-1-16	6/18(p)	6/18(p)	6/12	6/12
13-2-16	6/12	6/9	6/9	6/9
22-4-16	6/12	6/9	6/9	6/9
23-6-16	6/12	6/9	6/9	6/9

Table 3: Fundal examination

Fundus	Right	Left
22-01-2015	Showed dot and blot haemorrhages & NVE in all quadrants	Vitreous haemorrhage in the patient’s left eye obscured the optic disc and the fundus could not be examined in detail.
05-03-2015	NVE decreased, NVE present in superior and temporal quadrant laser marks	Resolving VH stable PDR
13-06-2015	Stable PDR	Resolved VH stable PDR
7-1-16 to 23-6-16	Stable PDR	Resolved VH stable PDR

CASE 2:

Patient

A 36-year-old male.

Chief complaint

Decreased vision in the right eye with floaters.

History of present illness

This patient was being followed-up by an ophthalmologist for vitreous haemorrhage due to bilateral DR. The DR had previously been treated with bilateral panretinal photocoagulation. & injection avastin. Patient visited Netraroga OPD of CARICD, CCRAS, and Punjabi Baugh New Delhi to prevent

PRP and treat the recurrent vitreous haemorrhage due to PDR.

Past medical history

The patient has type 2 diabetes since 5years with myopia. Ongoing medications while starting Ayurvedic drugs were as follows.

Insulin 40U/day

Gemer P2 BD

Family history

None of the patient’s relatives had a history of DR. His father had insulin dependent diabetes.

Findings on initial ocular examination

Upon initial ocular examination on 18 march 2017 the patient’s visual acuity (VA) was 6/60 B in Rt eye & 6/18 (P) in Lt eye. Intraocular pressure (IOP) was 13 mmHg in both eyes. The anterior eye segments showed no abnormalities. Funduscopy of the Lt eye showed postoperative laser marks & NVE in all quadrants. Vitreous haemorrhage in the patient’s Rt eye obscured the optic disc and the fundus could not be examined in detail.

Table 4: Follow-up course

Date	Visual acuity		pg		ph	
	Rt eye	Lt eye	Rt eye	Lt eye	Rt eye	Lt eye
18-3-17	CF from 3m	CF from 3m	6/60B	6/18p	-----	6/18p
20-5-17	CF from 3m	CF from 3m	6/60	6/12p	6/60B	6/18p
22-7-17	CF from 5m	CF from 5m	6/60	6/9	6/60B	6/12p
28-10-17	CF from 5m	CF from 5m	6/60B	6/9P	-----	6/12p
23-12-17	CF from 5m	CF from 5m	6/60	6/9	6/60B	6/9P
1-2-18	CF from 5m	CF from 5m	6/60	6/9	6/60B	6/9P
28-3-18	CF from 5m	CF from 5m	6/60	6/9	6/60B	6/9P
2-4-18	CF from 5m	CF from 5m	6/60	6/9p	6/60B	6/9P

Table 5: Fundal examination [Fig.1 & Fig.2]

Fundus	Right	Left
27-3-17	Vitreous haemorrhage in the patient’s Rt eye obscured the optic disc and the fundus could not be examined in detail.	Multiple Retinal capillary nonperfusion (CNP) no NVE noted
6/10/17	Resolving VH stable PDR PRP marks seen c/d ratio normal	PRP marks seen c/d ratio normal no NVE noted
23/3/18	Resolving VH stable PDR NVE noted PRP marks seen	PRP marks seen c/d ratio normal no NVE noted

CASE 3:

Patient

A 46-year-old male.

Chief complaint

Decreased vision in both eyes.

History of present illness

This patient was being followed-up by an ophthalmologist for bilateral DR. The DR had previously been treated with bilateral panretinal photocoagulation (6 sittings were completed). Patient visited Netraroga OPD of CARICD, CCRAS, Punjabi Baugh New Delhi to prevent PRP.

Past medical history

The patient had been diagnosed with type 2 diabetes 15years back. He began taking oral hypoglycemic drugs, and later on shifted to insulin along with oral drugs due to poor glycemic control. Ongoing medications while starting Ayurvedic drugs were as follows.

Insulin 25 U BD

Glyciphage VG 2 BD

Family history

None of the patient’s relatives had a history of DR.

Findings on initial ocular examination

Upon initial ocular examination on 23 apr 2018 the patient’s visual acuity (VA) was 6/18(p) in rt eye &

counting finger from distance of 5 metres in Lt eye. Intraocular pressure (IOP) was 17 mmHg in both eyes. The anterior eye segments showed no abnormalities. Funduscopy of the right eye showed PRP marks, PDR & NVE in all quadrants. Vitreous haemorrhage in the patient's left eye obscured the

optic disc and the fundus could not be examined in detail.

Findings on biochemical examination

Blood-test results were as follows: FBS 245, PPBS 282.

Table 6: Follow-up course

Date	Visual acuity		pg		ph	
	Rt eye	Lt eye	Rt eye	Lt eye		
23-4-18	6/18p	CF from 5m	6/9p	6/36	No further improvement	No further improvement
24-5-18	6/18	6/60	6/9	6/24	No further improvement	No further improvement

Table 7: Fundal examination

Fundus	Right	Left
23-4-18	PRP marks NVE noted PDR	Vitreous haemorrhage in the patient's left eye obscured the optic disc and the fundus could not be examined in detail
24-5-18	Stable PDR	Resolved VH

DISCUSSION

Durva is *Raktapittashamak*, *Raktastambhak* due to *Shitvirya*. *Kaishor guggulu* is *Rakta Prasadaka* and *Vatashamaka*. Drug used in *Mukhalepa* & *Pana* are *Amapachak*, *Kledahara* & *Rakta Prasadaka* & *Raktastambhak*. All the patients presented were in the stage of PDR with Vitreous haemorrhage which denotes *Raktapitta* & *Amavastha* of the disease. Patients were taking avastin injection and PRP which resolves Vitreous haemorrhage but frequency of PRP were reduced due to protocol followed. This may be attributed to the *Rakta Prasadaka* & *Raktastambhak* properties of protocol that prevents and resolves the Vitreous haemorrhage. *Durva* possesses anti glycaemic⁴ and wound healing properties.⁵ *Nasyakarma* itself is beneficial for removal of *Rakta* and *Vata Avarana* by virtue of *Srotoshodhana* property. *Guggulu* is one extraordinary drug that possesses *Anabhishtyandhi*, *Snigdha*, and *Sroto Shuhdhikaraka* actions. It is considered as the best drug for the management of *Avruta Anila*. The *Rookshana* property of drugs in *Kaishor Guggulu* like *Danti* (*Baliospermum montanum*), *Triphala* (*Terminalia chebula Retz.*, *Terminalia bellerica*,

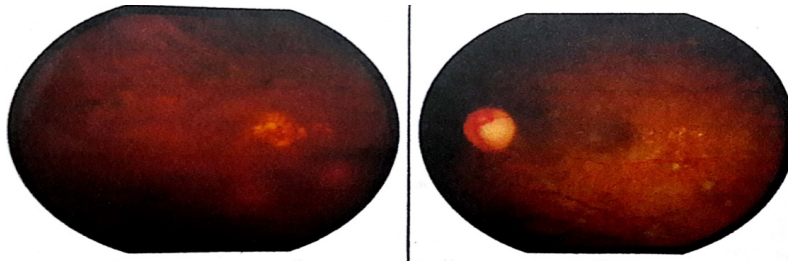
Emblica officinalis), *Vidanga* (*Embelia ribes*), and *Guggulu* (*Commiphora mukul*) act on abnormally accumulated *Kleda*. Regarding *Mukhalepa* & *Pana* drugs *Daruharidra* have Anti-oxidant activity and inhibits vascular permeability⁶ Berberine inhibits activator protein-1 activity, which is essential for inflammation in an in vitro study⁷ *Triphala*, *lodhra*, *Yashtimadhu*, possesses Anti-inflammatory, Anti-oxidant, Anti-microbial & Haemostatic action.⁸ Though PRP is a mean to stop bleeding but being *Ushna Chikitsa* it may not be considered as proper treatment modality as per Ayurveda & thus selected protocol may be adopted as an adjuvant to avastin for better clinical outcome than *avastin* plus PRP. This hypothesis is confirmed from the outcome of the treatment protocol adopted as all the three cases never took PRP after starting the Ayurvedic treatment.

CONCLUSION

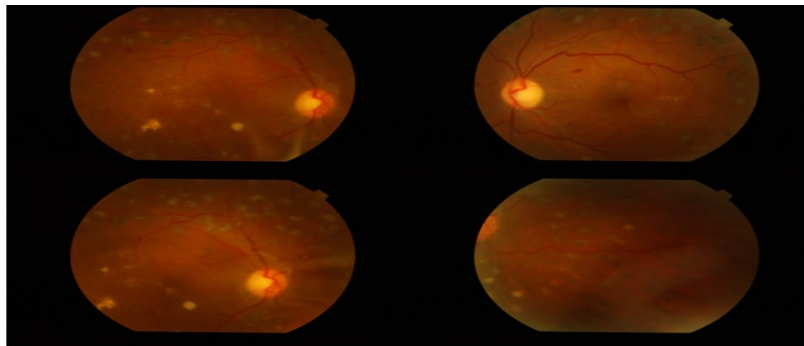
Selected treatment protocol is effective in management of DR and can be employed as an adjuvant to present modern management. It also has potential to avoid need for PRP.

REFERENCES

1. Santhakumari PK. A text book of ophthalmology in Ayurveda. 2nd ed. 2009: 219.
2. Charaka, Caraka Samhita edited by Tripathy Brahmananda, Chi- kitsa Sthana 28:63, 1999: 949
3. Trikamji J, Ram N, editors. Commentary Nibandha Sangraha of Dalhana on Susruta Samhita of Susruta, Sootra Sthana 15/9; Dosha Dhatu Mala Kshaya Vruddhi Vijnaneeyam. 1st ed. Varanasi: Chaukhambha Sanskrit Sansthan; 2012:69.
4. Chinaka, N.C., Edeh, I., Effects of Bermuda Grass (Cynodon dactylon) Extracts on Some Haematological Parameters of Streptozotocin-Induced Wistar Albino Rats, Journal of Natural Sciences Research www.iiste.org ISSN 2224-3186 (Paper) ISSN 2225-0921 (Online), 2015, 5:23,
5. Biswas TK, Pandit S, Chakrabarti S, Banerjee S, Poyra N, Seal T. Evaluation of Cynodon dactylon for wound healing activity. J Ethnopharmacol. 2017; 197: 128-37.
6. Zhang, M. F. and Shen, Y. Q. [Anti- diarrheal and anti-inflammatory effects of berberine]. Zhongguo Yao Li Xue Bao 1989;10(2):174- 176.
7. Fukuda, K., Hibiya, Y., Mutoh, M., Koshiji, M., Akao, S., and Fujiwara, H. Inhibition by berberine of cy- clooxygenase-2 transcriptional activity in human colon cancer cells. J Ethnopharmacol 1999;66(2):227- 233.
8. Neelam Sajwan, Jatayadi Oil: An Analytical Study, ejpmr, 2018,5(1), 163-166



Rt eye-Vitreous haemorrhage in the patient's Rt eye obscured the optic disc and the fundus could not be examined in detail. Lt eye-Multiple cnp no nve noted (27-03-2017)



6-10-17 Rt eye-Resolving vh stable pdr Prp marks seen c/d ratio normal. Lt eye-PRP marks seen c/d ratio normal no NVE noted

Source of Support: Nil

Conflict Of Interest: None Declared

How to cite this URL: Jadhav N. M. & Auti Swapnil: Management Of Diabetic Retinopathy With Ayurvedic Treatment Protocol - Case Reports. International Ayurvedic Medical Journal {online} 2018 {cited September, 2018} Available from: http://www.iamj.in/posts/images/upload/2185_2190.pdf