

INTEGRATED MANAGEMENT OF ULCERATIVE COLITIS - A CASE STUDY

Priyanka Ganguly¹, Sukesh A², Vinay Alva³

¹Final Year P.G. Scholar; ²Associate Professor;

Shalya Tantra Department, Alva's Ayurveda Medical College, Karnataka, India;

³Consultant Surgeon, Alva's Health Centre (Multi Speciality Hospital), Karnataka, India

Email: dr_priyanka11@rediffmail.com

ABSTRACT

Ulcerative colitis is the inflammatory disease which is causing ulcers in the colon and rectum. The prevalence rate of ulcerative colitis is 2-3% in the world which is characterized by Vomiting, Diarrhoea, Rectal bleeding, Abdominal pain and Weight loss. The symptom of Ulcerative colitis can be congruent with symptom of *Pravahika* in Ayurveda, such as *Atipravahana purisha*, *Udarsoola*, *Raktayukta purisha*. In *Ayurveda*, various treatment modalities have been illustrated for Ulcerative colitis as Diet, Medicine and *Panchakarma*. In this present study, the specific some drugs had been selected along with *Matra basti* with *Yasthimadhu taila* for treating the ulcerative colitis which shown gradually very effective and successful result while combined with Allopathy medication.

Keywords: Ulcerative colitis, *Pravahika*, *Shamana ousadhi*, *Matra basti*, *Panchakarma*.

INTRODUCTION

Ulcerative colitis is inflammatory bowel disease which causes the inflammation and ulcers in the rectum and colon. Ulcerative colitis occurs between 15 to 30 years of age. The main symptom of the disease is like Diarrhoea, along with blood and mucous, associated with weight loss and pain.¹⁻⁴ The main Symptom of the ulcerative colitis can be congruent with the symptom of *Pravahika* in *Ayurveda*, like *Atidrava purisha pravritti* (watery stools), *Atipravahana purisha* (repeated defecation), *udarshoola* (pain abdomen) and *raktayukta purisha* (blood mixed stool).⁵⁻⁸

In modern science, usually ulcerative colitis is treating by administering the anti-inflammatory steroids such as Prednisolone followed by

antidiarrheal (lomotil), antibiotics (sulphasalazine) and Multi-vitamins⁴ but the prognosis of this disease is very sluggish whereas in this present case study ,the prognosis of *Pravahika* is showing very effective, fast and successful consistent result by administering such *Ayurvedic* medications followed by *Matra basti* as *Panchakarma* treatment along with Allopathic medication.^{9,10}

AIM AND OBJECTIVES:-

The aims and objectives of this study were as follows –

- 1) To provide the efficacy of Ayurvedic treatment modalities to manage the ulcerative colitis.

- 2) To provide a safer treatment by reducing the need of steroids.
- 3) To provide an alternative treatment of surgical processes.

MATERIALS AND METHODS

➤ Selection of the patients

Age-23 yrs

Sex- Male

Religion – Hindu

Marital Status-Single

Economic Status- Middle

➤ Study centre

Alva's Health Centre (Multi speciality Hospital)

Moodbidri, Karnataka, India

O.P No. of Patient-28729

➤ Plan of study

- Proforma compiled with detailed clinical history and physical examination of the patients.
- Routine clinical investigations, before performing study.
- After confirming the diagnosis, patient was advised to follow treatment guideline strictly.

➤ Assessment criteria

- The improvement in the patient was assessed on the basis of relief in signs and symptoms of disease.
- Clinical examination was performed to detect the reduction of lesion as improvement criteria.

➤ Clinical examination of registered patients

➤ Present complain:

- ✓ *Rakta yukta purisha* or bleeding per rectum
- ✓ *Atidrava purisha* or Loose stools
- ✓ *Picchila, Saphena purisha* or Sticky and frothy stools
- ✓ *Udarashoola* or Pain abdomen
- ✓ Loss of appetite
- ✓ Loss of weight

➤ History of present illness:

The patient was apparently well one and half years before but since one and half year he was being suffering from bleeding per rectum, associated with frequently loose stools with mixing bleeding ,pain abdomen and loss of appetite. So, for betterment he approached to Alva's health centre (Multi speciality hospital) first on 16th Nov, 2016.

➤ General examination

P.R- 78 b/pm

B.P- 100/70 mm of Hg

Temp- 98.6⁰F

Clubbing- 2nd grade

C.V.S- N.A.D

R.S- N.A.D

Body Wt- 39 kg

➤ Systemic examination

Inspection: No abnormality detected in abdomen

Palpation: Tenderness

Percussion: Tympanic

Auscultation: Bowel sounds

➤ Investigation

Sigmoidoscopy- on 17/11/2016, showing multiple polyps and ulcers throughout the recto sigmoid region with mucous.

Biopsy Report: on 23/11/2016, suggestive acute ulcerative colitis.

- **Figure 1:** Sigmoidoscopy report -multiple polyps and ulcers throughout the recto sigmoid region with mucous.

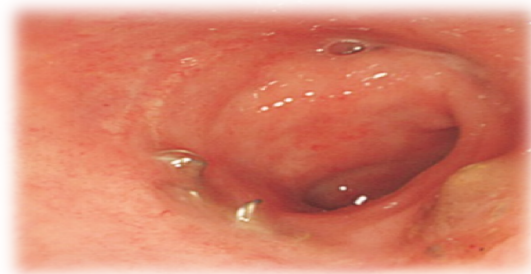

Table 1: TREATMENT PROTOCOL (For 2 weeks)

Allopathic Oral Medication	Ayurvedic Oral Medication	Panchakarma
✓ Tab Sulphasalazine 500mg one tab, once/day	✓ <i>Kutaja parpati</i> one tab twice/day	✓ <i>Matra basti</i> given with <i>Yasthimadhu taila</i> 20 ml
✓ Tab Mesocol 400mg half tab, twice/day	✓ <i>Bilwadi gutika</i> one tab thrice/day	
✓ Tab Folvit one tab, once/day	✓ <i>Chirabilwadi kashayam</i> 3tsf + half glass water twice/day before breakfast.	
	✓ <i>Syp Dnil</i> 3tsf twice/day	

➤ **Follow up**

The patient was follow up since one and half year

Last follow up on 08/05/2018-

Body wt – 42.74 kg

Appetite –Normal

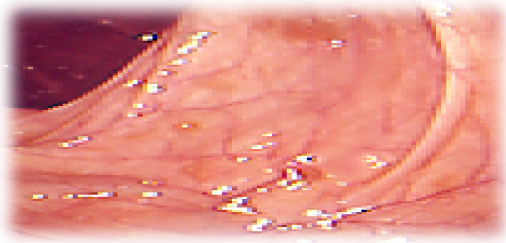
Bleeding per rectum- stopped

Loose motion- 1-2 times/day

Pain in abdomen – Occasionally

Sigmoidoscopy- on 08/05/2018, showing apparently normal report

➤ **Figure 2: Sigmoidoscopy report –Normal report after treatment**



➤ **RESULTS**

- Effects of *Ayurvedic* oral medication showing significant result after treating with this treatment protocol.
- *Matra basti* with *Yasthimadhu taila* offered significant relief in ulcer.

DISCUSSION

Effect of *Matraabasti*

Ulcerative colitis is a disease of *purisha vaha srotas* which is caused by *Pitta pradhana Vata doshas*. *Matra basti* helping to reduce the symptoms of

Ulcerative colitis or *Pravahika* where it is afflicted by *dosha* as *kapha, vata* and *agnimandya*.

- ♦ *Matra basti* having specific property which is beneficial for management of ulcerative colitis, such as –
 - *Sheetal*
 - *Pittahara*
 - *Madhura*
 - *Sangrahi*
 - *Sandhana*
 - *Vrana ropana*
 - *Pitta shamaka*

So, *Matra basti* helps to reduce the symptoms of Ulcerative colitis or *Pravahika* where it is afflicted by *dosha* as *kapha, vata* and *agnimandya*. So, *Matra basti* reduces inflammation, burning sensation, pain and cramps.

- ♦ *Yasthimadhu taila* has properties of *Pitta Vata shamana* and also *vrana shodana* and *ropana* which help in healing ulcers in the colon by *basti karma*. It also has *stambhana* properties that help in reducing the bowel frequency and check bleeding.

✓ **Effect of *Shamana Ousadhi***

Kutaja parpati, Bilwadi gutika, Chirabilwadi kashayam, these *shamana ousadhi* are having in general property which are beneficial for management of ulcerative colitis, such as-

- *Stambhana* property which stopping *Raktayukta purisha*.
- *Sangrahi* property which decreasing the frequency of bowel movements.

- *Pitta shamak* property which reduces passing *Raktayukta purisha*.
- *Vatanulomana* property which relieved *Udara shoola* and *Pravahana*.
- *Amapachana* property which corrects *Pravahana* and *Drave purisha pravritti*.
- ♦ Specific effect of *Kutaja parpati* – Antidysenteric, Antidiarrheal, Haemostatic, Anti-amoebic action.
- ♦ Specific effect of *Bilwadi gutika*- Antidysenteric, anti bacterial, reduces abdominal discomfort, improves digestion and appetite.
- ♦ Specific effect of *Chirabilwadi kashayam*-reduces constipation, indigestion, flatulence, anorexia.

CONCLUSION

Ayurvedic treatment of ulcerative colitis and other chronic inflammatory bowel diseases is effective in reducing disease symptoms and disease relapses and can reduce the need of conventional standard drugs. Moreover, the treatment is safe, inexpensive, easy to handle and well tolerated by the patients This present study suggests that *Matra basti* with *Yasthimadhu taila* followed by oral medication as *Kutaja parpati*, *Bilwadi gutika*, *Chirabilwadi kashayam* having significant result to treat Ulcerative colitis.

REFERENCES

1. Robbins. Basic Pathology. 7th Ed. New Delhi: Harcourt India Pvt. Ltd.; 2003.p. 572. 2.
2. Fauci AS, Hauser SL, Kasper DL, Longo DL, Jameson J L. Disorders of Gastro Intestinal System In: Braunwald E, editor. Harrison's Principles of Internal Medicines. 18th International Edition. Ch. 32, Vol. II. New Delhi: McGraw-Hill, Medical Publishing Division; 2002. p. 1770.
3. Inflammation bowel, D/S Crohn's Scleritis foundation of America.inc, 2006; 12: 1109
4. Somen Das. A concise text book of surgery. 3rd ed. Calutta: S. Das; 2001.p.1017.

5. Susruta Samhita, Dr. Ananat Ram Sharma, Chaukhambha Surbharati Prakashan, Varanasi, Chikitsa Sthana,2004; 38/113:482
6. Vaidya Jadavaji Trikamji Acharya., editor. 2nd ed. Varanasi: Chaukhamba Sanskrit Sansthan; Agnivesha, Charaka, Dridhabala, Charaka samhita Chikitsa Sthana, Atisara Chikitsa Adhyaya, 1990; 19/69-70 and 93-946.
7. Ashtanga hrudiyam, Dr Aanamureshwarakuntte and pt. Krishanasastrinavre, Chaukhambha Surbharati Parkashan, Varanasi, Sutra sthana, 2004; 19/57: 281
8. Dvivedi Vishvanath. 9th ed. Varanasi: Motilal Banarasidas Prakashan; Hindi commentator, Bhava prakash nighantu, 1998; 121.8.
9. Indradev Tripathi, Chakrapaniaadi virachita, Chakradutt Svimarsha "Vaidyaprabha" Hindi commentary, Chukambha publication, 2005; 53.
10. Kashinath shastri, Gorakhnaath Chaturvedi, Charak Samhita, Svimarshavidhyotani, Hindicommentary, 2nd part, Chukambha publication, 2009; 447.

Source of Support: Nil

Conflict Of Interest: None Declared

How to cite this URL: Priyanka Ganguly et al: Integrated Management Of Ulcerative Colitis - A Case Study. International Ayurvedic Medical Journal {online} 2018 {cited September, 2018} Available from: http://www.iamj.in/posts/images/upload/2233_2236.pdf