

A VARIATION IN THE FORMATION OF PORTAL VEIN: A CASE REPORT

Dipti G Godbole¹, Gururaj Jahagirdar²

¹Assistant Professor; ²Associate Professor;

Department of Rachana Shareera, Sri Dharmasthala Manjunatheshwara Institute of Ayurveda & Hospital, Bengaluru, Karnataka, India

Email: dipti.bams@gmail.com

ABSTRACT

Portal vein is the largest intra-abdominal vein situated in the right upper quadrant of the abdomen. This drains blood from the abdominal part of the gastrointestinal tract from the lower third of esophagus to halfway down the anal canal including spleen, pancreas and gall bladder. It is formed by the union of superior mesenteric vein and splenic vein behind the neck of the pancreas. During our routine UG dissection in the Department of Rachana Shareera at SDMAH, Bengaluru, a variation was found in the formation of portal vein. There was Inferior mesenteric vein terminating into Superior mesenteric vein and later, Splenic vein joining into Superior mesenteric vein to form the portal vein. The detail study of this variation is discussed in this paper.

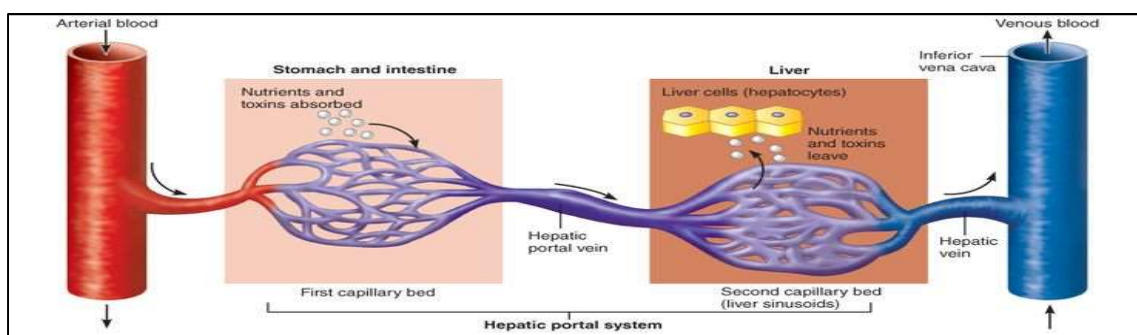
Keywords: Portal vein, Superior mesenteric vein, Inferior mesenteric vein, Splenic vein.

INTRODUCTION

The arteries supplying an organ end in a set of capillaries from which blood is collected by veins that carry it to the heart. In some cases, however, the

veins from an organ enter another organ where they divide into a second set of capillaries (sinusoids). Such an arrangement is called portal system.

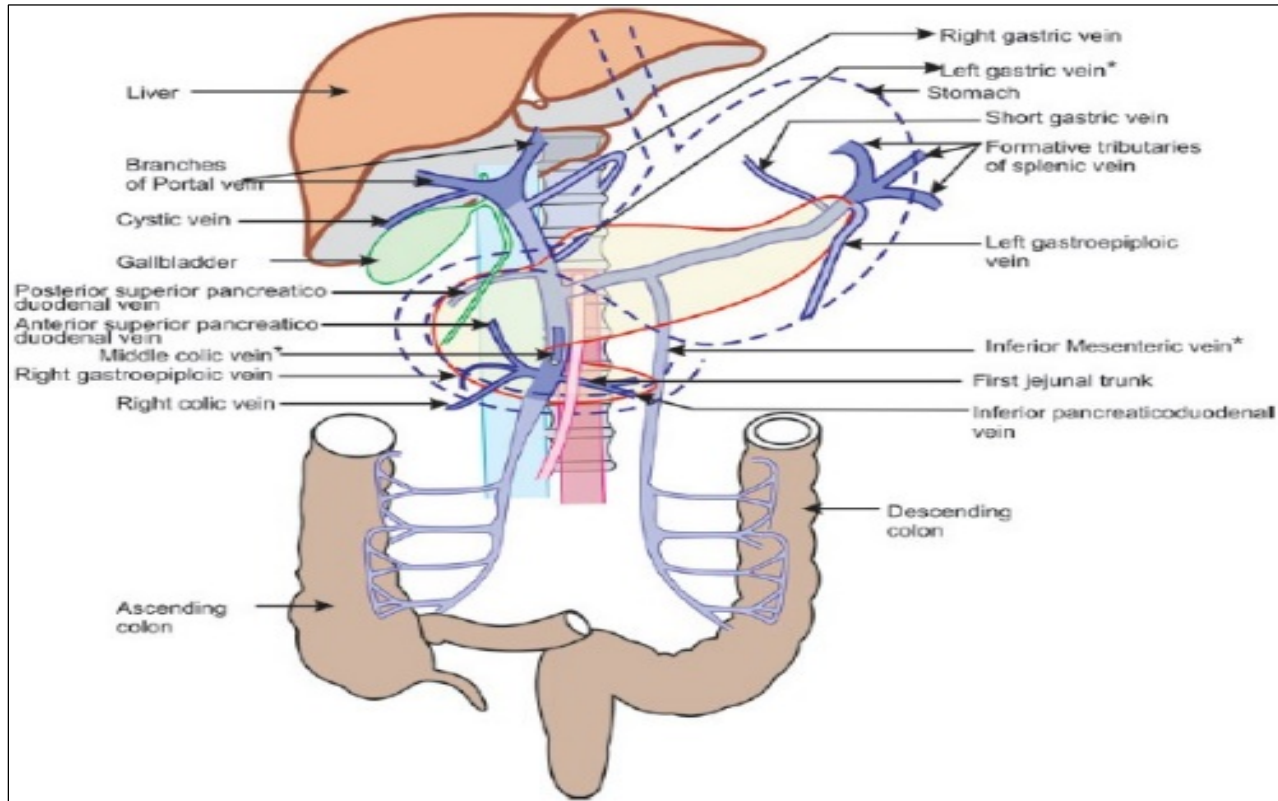
Fig 1: Showing portal venous system formation



The portal vein is about 8-centimeter-long, 2cm width, with a normal diameter of 13-16mm(1cm), formed by the union of superior mesenteric vein and splenic vein behind the neck of the pancreas, in front of inferior vena cava at the level of second lumbar vertebrae. It ascends to the right behind the first part of the duodenum and enters the free margin of the

lesser omentum^[4]. It is now separated by inferior vena cava by the epiploic foramen and as it enters the porta hepatis, it is separated from the inferior vena cava by the caudate process of liver^[2]. Entering through the porta hepatis, it divides into right and left terminal branches which further break up into sinusoids.

Fig 2: Normal Anatomy-formation and relation of portal vein



The blood from the sinusoids is collected by hepatic veins that join the inferior vena cava^[4]. It also receives blood from the inferior mesenteric, gastric, and cystic veins. 75% of the blood supplied to the liver comes from the portal vein, but it only supplies 50% of the oxygen supply to the liver^[5].

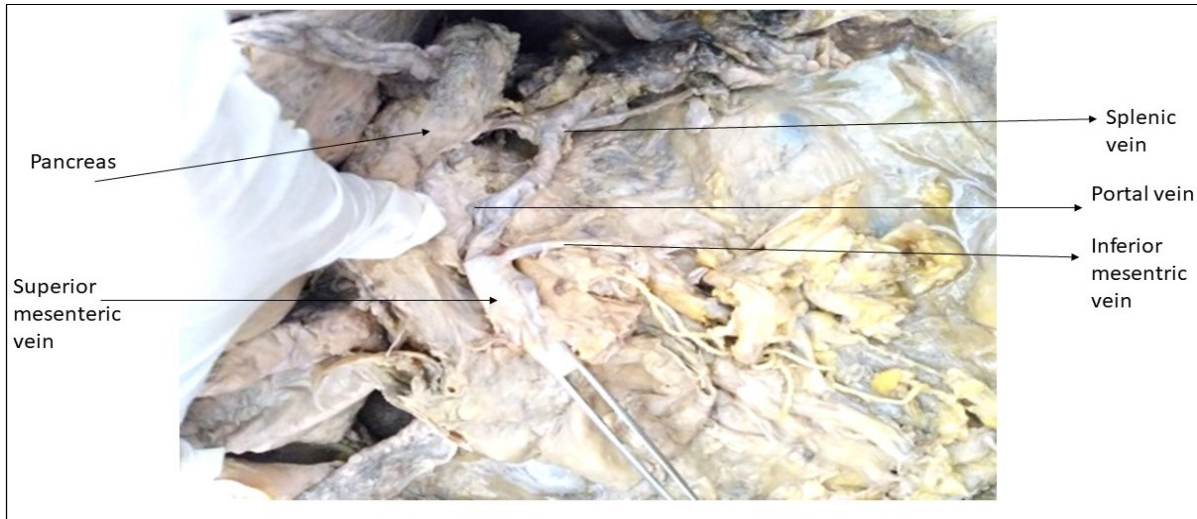
During our routine UG dissection of the mesenteric vessels of the abdomen in the Department of Rachana Shareera at SDMIAH Bengaluru, a

variation was encountered in the formation of portal vein in a 55 years old female cadaver.

OBSERVATIONS

Inferior mesenteric vein was terminating into Superior mesenteric vein and later Splenic vein was joining into Superior mesenteric vein to form the portal vein. Other than this, there were no other additional changes noted in and around this region.

Figure 3: Showing formation of portal vein in a dissected cadaver



DISCUSSION

The variation in the formation of portal vein is clearly understood by studying the embryological origin of abdominal vessels.

In an embryo, the paired vitelline veins transport blood from the yolk sac to the sinus venosus. During the fourth to fifth weeks of embryonic life, three anastomoses form between the vitelline veins and they are the cranial-ventral, dorsal and caudal-ventral anastomoses, named according to their anatomical position and relationship to the primitive foregut that will become the duodenum. From the formation of these anastomoses to the third month of development, there is selective involution of the venous network that eventually forms the portal vein.

It has been proposed that aberrations in the process of involution can result in anatomical variations within the portal venous system^[3].

The complexity of hepatic interventions performed now by interventional radiologists and surgeons, including portal vein embolization, anatomic resection, and transplantation, gives us a better understanding of normal and variant portal vein anatomy which is truly important in today's era.^[6]

Benninger described two new terminologies regarding the normal formation of portal vein. He opined that inferior mesenteric joins splenic vein to form "*splenomesenteric*" vein which should be at least 3cm before joining superior mesenteric to be called it as *splenomesenteric*. He named it so, because of its high percentage of incidence and clinical relevance. When inferior mesenteric directly joins with the superior mesenteric instead of splenic vein, then this common vein is known as "*common mesenteric vein*". The splenomesenteric vein is informally termed as "*Benninger's vein*".^[1]

Type I–Portal vein is formed by confluence of superior mesenteric vein and splenic vein.

Type II–Portal vein is formed by confluence of superior mesenteric vein, inferior mesenteric vein and splenic vein.

Treves found type II mainly in 44%,10 cases (15.38%) reported by *Wunnee Chaijarookhanarak et al*, *Purcell & coworkers* found this in 53%, *Woodburne* observed this in 40%, 12.5% reported by *Aktan, Rajashree SR et al* showed type II in 47.5% population^[3].

CONCLUSION

The awareness of existence of these variations are critically of much more importance in surgical resection and transplant patients, especially during pretreatment planning, just to reduce the incidence of complications. As the present case showed the confluence of Superior mesenteric vein, Inferior mesenteric vein and Splenic vein forming the portal vein, so the pattern of termination of tributaries needs to be borne in mind before operating, to prevent intraoperative hemorrhage^[3].

Variations of its formation were earlier found in literatures. Termination of tributaries of portal vein is of prime importance for surgeons to perform surgeries on pancreas, duodenum, liver and for interventional procedures.

Thus, having thorough knowledge regarding the variant vascular anatomy certainly, can have critical implications during surgery and interventional radiological procedures^[1].

REFERENCES

1. Rajashree Sheelawant Raut, B.H. Bahetee, Study of variations in the formation of portal vein, SJAMS, 2015; 3(3E): Page no.- 1373.
2. Inderbir singh's text book of anatomy- 6th edition, Volume two- Thorax, Abdomen and Pelvis, Section 5, Pg.no-255-256.
3. Rapotra M, Singh R, Anomalous Formation of The Portal Vein and Its Clinical Relevance: A Case Report, IJRAS, Vol.3, Issue 9, August 2016, ISSN: 2394-4404, Page no's: 88-90.
4. Portal vein anatomy: Formation, tributaries and portocaval anastomosis - <http://teachinganatomy.blogspot.com/2013/03/Portal-vein-and-Porto-caval-anastomosis.html>
5. Dr Henry Knipe, Dr Jeremy Jones, et al- <https://radiopaedia.org/>, Systems: Vascular, Hepatobiliary, Section: Anatomy, **rID:** 5732
6. Anne M. Covey, Lynn A. Brody, George, Getraidman, Constantinos T. Sofocleus, and Karen. T. Brown, Incidence, Patterns, and Clinical Relevance of Variant Portal Vein Anatomy,

American Journal of Roentgenology 2004 183:4, Abstract part.

Source of Support: Nil

Conflict Of Interest: None Declared

How to cite this URL: Dipti G Godbole & Gururaj Jahagirdar: A Variation In The Formation Of Portal Vein: A Case Report. International Ayurvedic Medical Journal {online} 2018 {cited December, 2018} Available from: http://www.iamj.in/posts/images/upload/2445_2448.pdf