

## MANAGEMENT OF *MOOTRA-GRANTHI* (URETHRAL CARUNCLE) WITH *AGNI-KARMA* - A CASE REPORT

Ram Sinha<sup>1</sup>, Prashant Saini<sup>2</sup>, P. Hemantha Kumar<sup>3</sup>

<sup>1</sup>M.S.Scholar, <sup>2</sup>Ph.D Scholar, <sup>3</sup>Professor & Head

P.G. Department Of Shalya Tantra, N.I.A., Jaipur, Rajasthan, India

Email: [dr.ramsinha01@gmail.com](mailto:dr.ramsinha01@gmail.com)

### ABSTRACT

*Acharya Sushruta* described *Mootra-Granthi* in *Sushruta Samhita Uttara Tantra*. This can be correlated with urethral caruncle. A urethral caruncle is a benign cutaneous condition characterized by distal urethral lesions usually originating from the posterior lip of the external urethral meatus and often observed in elderly postmenopausal women. The lesion is typically asymptomatic, although some women present with associated complaints. We present a case of *Mootra-Granthi* (Urethral caruncle) in a 70 years old woman. The case was evaluated with physical examination. *Agnikarma* under local infiltration anesthesia was performed. There were no complications during and after *Agnikarma*. No recurrence was noticed during follow-up and complaints regarding micturation were also resolved.

**Keywords:** *Mootra-Granthi*, Urethral caruncle, *Agnikarma*

### INTRODUCTION

*Acharya Sushruta* described 12 types of *Mootraghata* in 58<sup>th</sup> chapter of *Sushruta Samhita Uttara Tantra*<sup>1</sup>. *Mootra-Granthi* is given as a type of *Mootraghata* among them. In this disease a *Vritta*, *Alpa*, *Sthira*, *Vedana Yukta Granthi* occurs inside the *Bastimukha* which interrupts the *Mootramarga*<sup>2</sup>.

The word caruncle means a small, fleshy outgrowth, such as a fowl's wattles. Urethral caruncle is defined as a highly vascular polypoid lesion originating from the posterior

wall of the external urethral meatus of women. It is the most common benign tumour of the female urethra occurs primarily in postmenopausal women. On examination, caruncles most often appear clinically as a soft, raspberry-like, pedunculated pink or reddish exophytic lesion at the urethral meatus. It is usually small in size but can grow up to 1 cm or more in diameter. These are epidermal growths which consist of highly vascular connective tissue stroma infil-

trated with pus cells and loosely surrounded with transitional and squamous epithelial cells<sup>3</sup>. The most important risk factor in its etiology is hypo-oestrogenemia. The first step in the development of a urethral caruncle is likely distal urethral prolapse caused by urogenital atrophy due to estrogen deficiency. Chronic irritation, where the urethral mucosa is exposed, contributes to the growth, hemorrhage, and necrosis of the lesion. Most urethral caruncles are asymptomatic and are incidentally noted on perineal examination; however, some may be painful and others may be associated with frequency of micturition, dysuria and dyspareunia. Many individuals with a urethral caruncle present with bleeding or, more commonly, with the patient noticing blood on undergarments<sup>4</sup>.

Although the initial medical treatment of urethral caruncle is topical oestrogen and anti-inflammatory treatment but it is believed that the most effective form of treatment is total excision. Total excision is preferred because the mass can be large enough to make urinating difficult; there is also a small chance of malignancy. It can also be a sign of disease, such as carcinoma, so total excision is now favoured<sup>5</sup>. The caruncles can be removed by diathermy coagulation of the base of the stalk<sup>6</sup>. Symptomatic conservative treatment can be given for associated complaints. Pathology studies are necessary to distinguish carcinoma of the urethra from urethral caruncles. Caruncles can grow back in some instances. Urethral caruncle can accompany the skin changes related to lowered oestrogen levels. They can become a source of chronic haematuria, infection, and urethritis<sup>7</sup>.

*Acharya Sushruta* has preached, practiced and documented the details of *Agnikarma*<sup>8</sup>. *Agnikarma* is an asset of *Ayurveda* surgeons which has been used widely in the clinical practice

since time immemorial. *Agnikarma* is one among the Para surgical procedures which have been mentioned in *Ayurveda* literature. *Agnikarma* also helps in painful conditions-  
अग्निकर्म दूषितरक्तपित्तयोः प्रसादाय वेदनोपशमाय च<sup>9</sup>।

### CASE STUDY

A 70 years old female patient presented to the O.P.D. of P.G. Department of *Shalya Tantra*. The patient had painful swelling at external urethral meatus since 2 years with difficulty in urination and burning micturition since 1 month. She had Menopause before 20 years and had H/O Vaginal hysterectomy for uterine prolapse before 3 years. The physical examination revealed a 2 × 1.5 cm. pinkish mass that was soft on palpation, originating from the posterior lip of the external meatus. After proper history taking and physical examination she was diagnosed as a case of *Mootra-Granthi* (Urethral caruncle). All routine investigations were performed and no specific aetiology was found so patient posted for *Agnikarma*. All aseptic measures were employed during procedure. *Agnikarma* was done under local infiltration anesthesia (2% lignocaine) with thermal cautery. After complete hemostasis, ASD was done and patient shifted to ward with urethral catheter in situ. No complication occurred during or after the procedure. The urethral catheter was withdrawn on 7<sup>th</sup> post-operative day and patient was discharged. Wound was completely healed within 20 days. The patient was followed up weekly up to one month after complete healing of wound.

### RESULT AND DISCUSSION

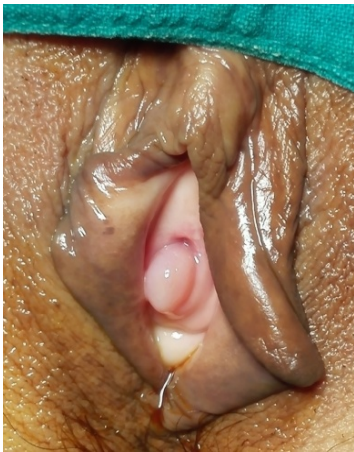Although a urethral caruncle can be seen in the prepubertal period, it is often observed in the

postmenopausal period as in our case. A urethral caruncle often does not cause symptoms in patients; it is a cosmetic disorder. A urethral caruncle can signal certain disorders and these should be looked for. These disorders include urethral thrombosis, pseudoneoplastic lesion, lymphoma, clitoral vein thrombosis, ureteral polyps, malignant melanoma, carcinoma, intestinal heterotype, angiomatous lesions and distal urethral stenosis.

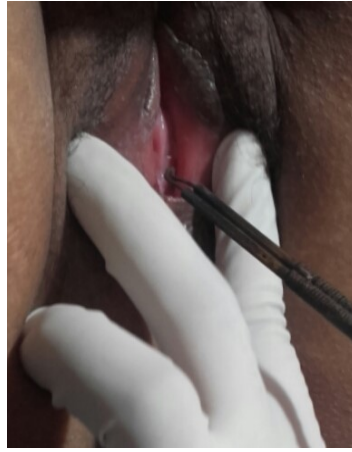
During intra operative period whole procedure was performed in local infiltration anesthesia so

no pain was felt by the patient. No any analgesic was advised to patient after the procedure. It shows the effect of *Agni Karma* in painful conditions.

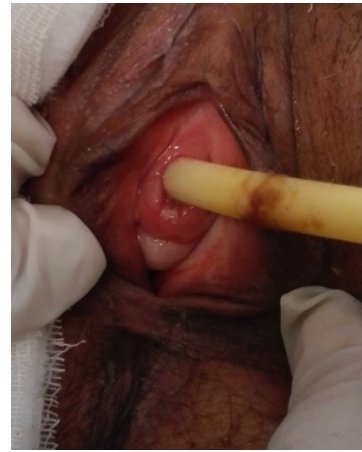No prolapse of urethral mucosa or recurrence of mass was noted during follow-up. It is probably due to necrosis of tissue by *Agnikarma* because *Agni* being *Ushna* and *Tikshna* in *Guna* does the action of *Vrana Shodhana* via *Sravaharana*, *Vikruta Twak* and *Mamsa Dahana*, *Sankochana* of *Sira*.



**Before Agnikarma**



**During Agnikarma**



**After Agnikarma**

## CONCLUSION

The present case shows very hopeful results of *Agnikarma* on the *Mootra-Granthi* (Urethral caruncle) as it is safe, cost effective, very good haemostatic and successful treatment of urethral caruncle with no recurrence. To make firm the above theory the study should be carried out in large sample size.

## REFERENCES

1. *Sushruta Samhita* of *Acharya Sushruta* edited with *Ayurveda Tatva Sandipika Hindi* Commentary by *Kaviraj Ambikadutta Shastri, Chaukhambha Sanskrit*

*Sansthan, Varanasi*, Edition: Reprint 2010, *Uttara Tantra* 58/3-4, P-539.

2. *Sushruta Samhita* of *Acharya Sushruta* edited with *Ayurveda Tatva Sandipika Hindi* Commentary by *Kaviraj Ambikadutta Shastri, Chaukhambha Sanskrit Sansthan, Varanasi*, Edition: Reprint 2010, *Uttara Tantra* 58/18-19, P-542.
3. Bailey & Love, Short practice of surgery 26th edition, 2013, Chapter 78, P-1368.
4. <https://emedicine.medscape.com/article/443099-overview#a8>
5. <https://www.ncbi.nlm.nih.gov/pmc/articles/PMC4001659/>
6. Bailey & Love, Short practice of surgery 26th edition, 2013, Chapter 78, P-1368.
7. [https://en.wikipedia.org/wiki/Urethral\\_caruncle](https://en.wikipedia.org/wiki/Urethral_caruncle)

8. *Sushruta Samhita* of Acharya Sushruta edited with *Ayurveda Tatva Sandipika Hindi Commentary* by Kaviraj Ambikadutta Shastri, Chaukhambha Sanskrit Sansthan, Varanasi, Edition: Reprint 2010, *Sutra Sthana* 12.
  9. *Sushruta Samhita* of Acharya Sushruta edited with Nibandhasangraha Commentary of Dalhanacharya by Acharya Yadavji Trijumji, Chaukhambha Surbharati Prakashan, Varanasi, Edition: Reprint 1994, *Sutra Sthana* 12/13, P-46.
- 

**Source of Support: Nil**

**Conflict Of Interest: None Declared**

How to cite this URL: Ram Sinha et al: Management Of Mootra-Granthi (Urethral Caruncle) With Agnikarma - A Case Report. International Ayurvedic Medical Journal {online} 2018 {cited February, 2018} Available from: [http://www.iamj.in/posts/images/upload/491\\_494.pdf](http://www.iamj.in/posts/images/upload/491_494.pdf)