

CLINICAL EFFICACY OF FISTULOTOMY FOLLOWED BY KSHARKARMA IN THE MANAGEMENT OF LOW ANAL FISTULA - A CASE SERIES

Monica Shrestha¹, T. S. Dudhamal²

Department of Shalya Tantra, Gujarat Ayurveda University, Jamnagar, Gujarat-361008, India

Email: Shresthamonica33@gmail.com

ABSTRACT

The state of anal fistula treatment in the modern world is a challenge due to, its recurrence nature. Therefore, there is a vital need to have a second look on the subject and to develop a method which would provide a fairly successful and acceptable measure for the treatment of fistula. *Ksharsutra* holds upper hand in the treatment of fistula-in-ano but there are certain shortcomings associated with it like prolonged healing time, delayed wound healing, pain during *Ksharsutra* change etc. The aim of this intervention (*Fistulotomy* with *Ksharkarma*) is to combat the shortcoming of the *Ksharsutra* and to utilize the advantages of the *Kshara*. In this regard five cases treated with *Fistulotomy* and *Ksharkarma* are discussed. The wound was assessed weekly and it was observed that pain, discharges and swelling reduced and early healthy granulation was observed. Average days taken for wound healing were 6.2 weeks and Average unit healing time was 8.41 days per cm. The mean duration of healing of fistula is less compared to *Ksharsutra* as unhealthy granulation tissue is removed during *fistulotomy* and what is left is debrided by the local application *Tikshna Apamarga Kshara*.

Keywords: Ayurveda, *Apamarga Kshara*, *Bhagandara*, *Fistula-in-ano*, *Fistulotomy*, *Kshara*, *Ksharsutra*.

INTRODUCTION

Fistula-in-ano is a very bothersome condition as it is a source of constant anxiety and social stigma for the patient which can also be understood by fact that Sushrut who is considered as father of Surgery included it among *Mahagada*.^[1] Wound contamination and consequent sepsis is one of the major hurdles in management of this disease. The recurrence of disease is a constant threat. Sushrut suggested laying open the fistulous tract followed by *Ksharkarma* or *Agnikarma* for the management of *Bhagandara*.^[2] *Pratisarniya Kshara* (Local application of *Kshara*) is indicated in *Bhagandara*.^[3] Charaka also suggested *Patana karma* (Incision) followed by *Tail daha* (cauterization by hot oil).^[4]

The state of anal fistula treatment in the modern world is a challenge due to its recurrence. Therefore, there is need to have a second look on the subject and to develop methods which would provide a fairly successful and acceptable measure for the treatment of fistula.

Ksharsutra application in *fistula-in-ano* takes upper hand in the various surgical modalities available for the treatment of this ano-rectal conditions but it is associated with excruciating pain while changing the *Ksharsutra*, false healing, delayed healing, skin erosion, and wound infection. Due to long duration of treatment patient's compliance is less and many dropouts during treatment.

The *Kshara* in *Ksharsutra* paves way for debridement of unhealthy fibrous tissue lining the fistulous tract thus helps in healing the fistulous tract with healthy granulation from the base of the wound. Thus, laying open the tract (*Fistulotomy*) followed by *Ksharkarma* (local application of *Tikshna Apamarga Kshara*) was done in these 5 cases to combat with the aim of reducing the healing time and combat the shortcoming of the *Ksharsutra* and utilize the advantages of the *Kshara*.

Methodology of Fistulotomy and Ksharkarma

Pre-operative:- Informed written consent was taken. Part was prepared a night before operation. Injection T.T 0.5cc IM was given and Inj. Lignocaine 2% sensitivity test was done. Patient was kept nil by mouth 6 hours prior to procedure. Proctoclysis enema was given in early morning 3 hours before operation.

Operative Procedure: Under spinal anesthesia or local anaesthesia in lithotomy position painting and draping done. First patency test was done by pushing methyl blue dye through external opening to locate the direction and cavity of fistula. Then lubricated index finger was introduced gently into the anal canal and with other hand a lubricated probe was introduced through the external opening of the fistula. The index finger inside the anus guided the probe. The probe was progressed towards the internal

opening. Forceful probing was avoided. After reaching the internal opening, the tip of the probe was brought out through the anal canal. The tract was layed open (Fistulotomy) and the wound edges were trimmed than *Tikshna Apamarga Kshara (Ksharkarma)* was applied then covered by a gauze piece and left for approximately 30 seconds. Later, Fistlotomy wound was flushed with lemon juice followed by normal saline to remove the *Kshara*.

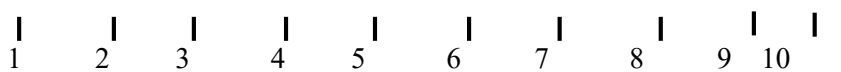
Post – operative:-

From next evening, patient was advised to take sitz bath with *Panchavalkala* decoction and then antiseptic dressing with *Ksharaplota* and *Matra basti* with *Jatyadi taila* was done daily. *Varun shrigru guggulu* was prescribed daily in the dose of 1gm three times per day orally with luke warm water after meal till complete cure.

Assessment Criteria

- **Pain :** *Visual Analogue scale (VAS)*

An imaginary line of 10 cm will be marked to indicate intensity of pain to assess the pain intensity in the patients.



Discharge:

Grade 0	No Discharge
Grade 1	Mild Discharge (if wound wets 1 gauze piece)
Grade 2	Moderate Discharge(if wound wets 2 gauze pieces)
Grade 3	Severe Discharge (if wound wets more than 2 gauze piece)
Grade 4	Excruciating Discharge (continuous and profuse)

Itching:

Grade 0	No itching
Grade 1	Mild and occasional
Grade 2	Moderate and occasional
Grade 3	Moderate and frequent
Grade 4	Severe and continuous

- Size of wound:
- Unit healing time

$$UHT = \frac{\text{Total number of days required for complete cutting of tract}}{\text{Initial length of wound}} = \text{days/cm}$$

Case no. 1-

A 47 years old male patient visited OPD with fever and chills; he felt an abscess like lump at anal verge with severe pain in ano which subsides spontaneously after some pus discharge. On perineal examination in lithotomy position

external opening was seen at 6 o'clock approximately 3 cm from anal verge. On digital examination internal opening was felt at 6 o'clock. TRUS (Transrectal ultrasonography) was done to confirm the diagnosis. As per TRUS report, 24 x 21 x 29 mm sized perianal abscess in between 6- 7 o'clock

position, 11 mm proximal to perianal skin. 17 mm long linear non-branching fistula in right perianal region with external opening at 7 o'clock and internal opening at 6 o'clock position. Internal opening at 6 o'clock position just at anal verge. Hence, based on clinical findings and TRUS the case was diagnosed as a case of *Bhagandara* (Transphincteric Low anal fistula). Patient was treated by Fistulotomy followed by *Tikshna Apamarga Kshara* Application. Fistula healed completely within 4 weeks. Unit healing time was 9.3 days per cm. Post operative TRUS showed fibrosis at 6 o'clock.(Figure 1)

Case no. 2

A 45 years old male patient visited OPD with complaints of swelling and severe pain in ano. On perineal examination in lithotomy position external opening was seen at 6 o'clock approximately 3.3 cm from anal verge. On digital examination internal opening was felt at 6 o'clock. TRUS was done to confirm the diagnosis. As per TRUS, 33 mm long linear non-branching fistula in perianal region with external opening at 6 o'clock and internal opening at 6 o'clock position. Hence, based on clinical findings and TRUS the case was diagnosed as a case of *Riju Bhagandara* (Transphincteric Low anal fistula). Fistula healed completely within 6 weeks. Unit healing time was 7 days per cm. Post operative TRUS showed superficial subcutaneous hypoechoic fibrosis at 6 o'clock. (Figure 2)

Case no. 3

A 40 years old male patient visited OPD, with boil at perianal region which was not associated with pain, pus discharge or bleeding. There was excessive burning pain in ano. On perineal examination in lithotomy position external opening was seen at 6 o'clock approximately 5 cm from anal verge. On digital examination internal opening was felt at 6 o'clock. TRUS was done to confirm the diagnosis. As per TRUS report, 45 x 17 x 25 (vol. 11 cc) sized intramural and perianal abscess at 6 mm at 6 o'clock and internal opening at 6 o'clock position. Internal opening is 2 mm proximal to anus. Hence, based on clinical findings and TRUS the case was diagnosed as a case of *Riju Bhagandara* (Transphincteric Low anal fistula). Fistula healed completely within 6 weeks. Unit healing time was 7 days per cm. Post operative TRUS showed superficial subcutaneous hypoechoic fibrosis at 6 o'clock.(Figure 3)

Case no. 4

A 44 years old male patient visited OPD with complaints of burning pain in ano and soiling of his underclothes. On perineal examination in lithotomy position external opening was seen at 5o'clock approximately 4 cm from anal verge. On digital examination internal opening was felt at 6 o'clock. TRUS was done to confirm the diagnosis. As per TRUS report, 3.8 cm long linear non-branching fistula was seen in left perianal region with external opening at 5 o'clock position. Internal opening is 2.3 mm proximal to anus. Hence, based on clinical findings and TRUS the case was diagnosed as a case of *Riju Bhagandara* (Intersphincteric Low anal fistula). Patient was treated by Fistulotomy followed by *Tikshna Apamarga Kshara* Application. Fistula healed completely within 5 weeks. Unit healing time was 8.75 days per cm. Post operative TRUS showed superficial subcutaneous hypoechoic fibrosis at 6 o'clock. (Figure 4)

Case no. 5

A 38 years old male patient visited OPD with complaints of boil in perianal region, which was associated with pus discharge. On perineal examination in lithotomy position 2 external openings were seen at 6 and 10 o'clock approximately 3.4 cm and 3 cm from anal verge. On digital examination internal opening was felt at 6 and 10 o'clock respectively. TRUS was done to confirm the diagnosis. As per TRUS report, 34 mm long x 5mm wide calibrated linear non-branching fistula in Right perianal region with external opening at 10 o'clock and internal opening at 9 o'clock position. Internal opening is 7 mm proximal to anus. Hence, based on clinical findings and TRUS the case was diagnosed as a case of *Riju Bhagandara* (Transphincteric Low anal fistula). Fistula healed completely within 8 weeks. Unit healing time was 10 days per cm. Post operative TRUS showed superficial fibrotic scar at 9 - 10 o'clock.(Figure 5)

Observation and Results:

In all the cases fistulotomy followed by *Ksharkarma* (local application of *Tikshna Apamarga Kshara*), the wound was assessed weekly and it was observed that pain discharges and swelling reduced and healthy granulation was observed. (Table 1) Average days taken for wound healing were 6.2 weeks Average unit healing time was 8.41 days per cm.

Table 1: Observation on weekly assessment

	CASE 1		CASE 2		CASE 3		CASE 4		CASE 5	
	BT	AT	BT	AT	BT	AT	BT	AT	BT	AT
PAIN	3	0	2	0	2	0	2	0	3	0
ITCHING	0	0	1	0	0	0	0	0	0	0
DISCHARGE	3	0	0	0	2	0	3	0	4	0
LENGTH OF WOUND (in cm)	3	0	5	0	6.5	0	4	0	6.2	0
UHT (Unit healing time) Days/ cm	9.3		7		7		8.75		10	
Time taken for complete healing (in weeks)	04		08		06		05		08	

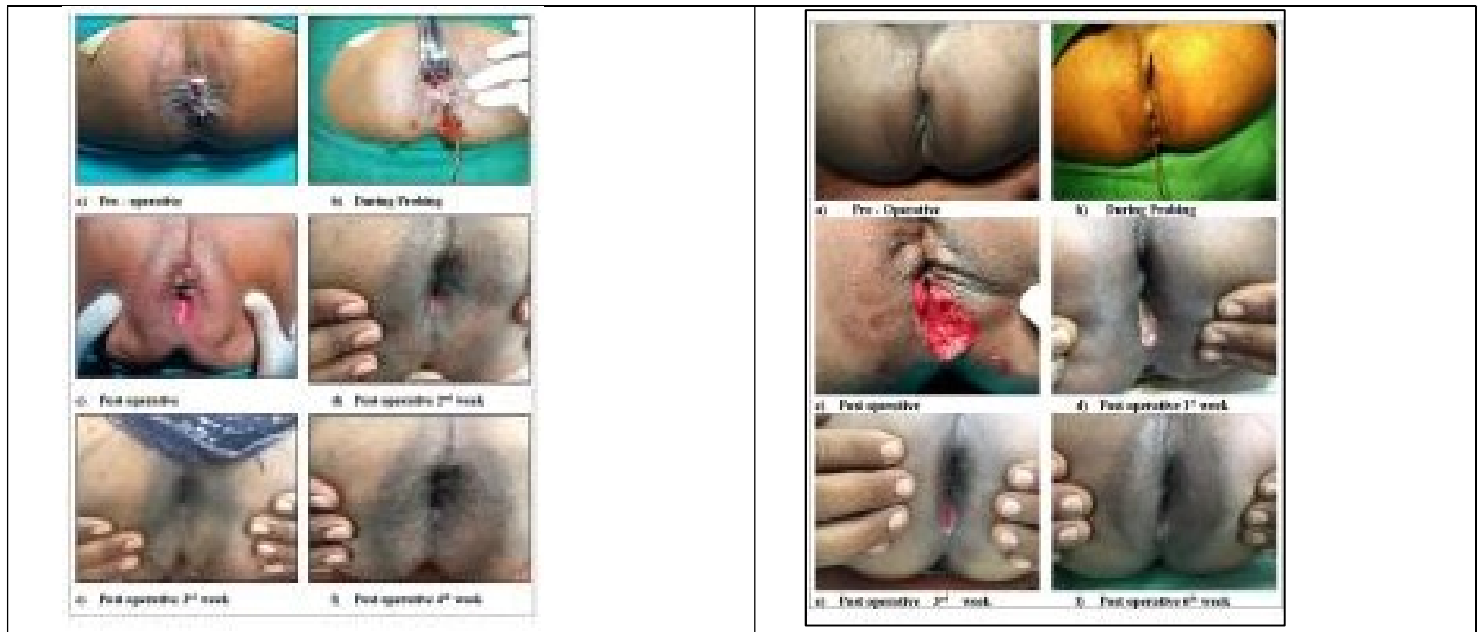

Figure 1: CASE 1

Figure 2: CASE 2

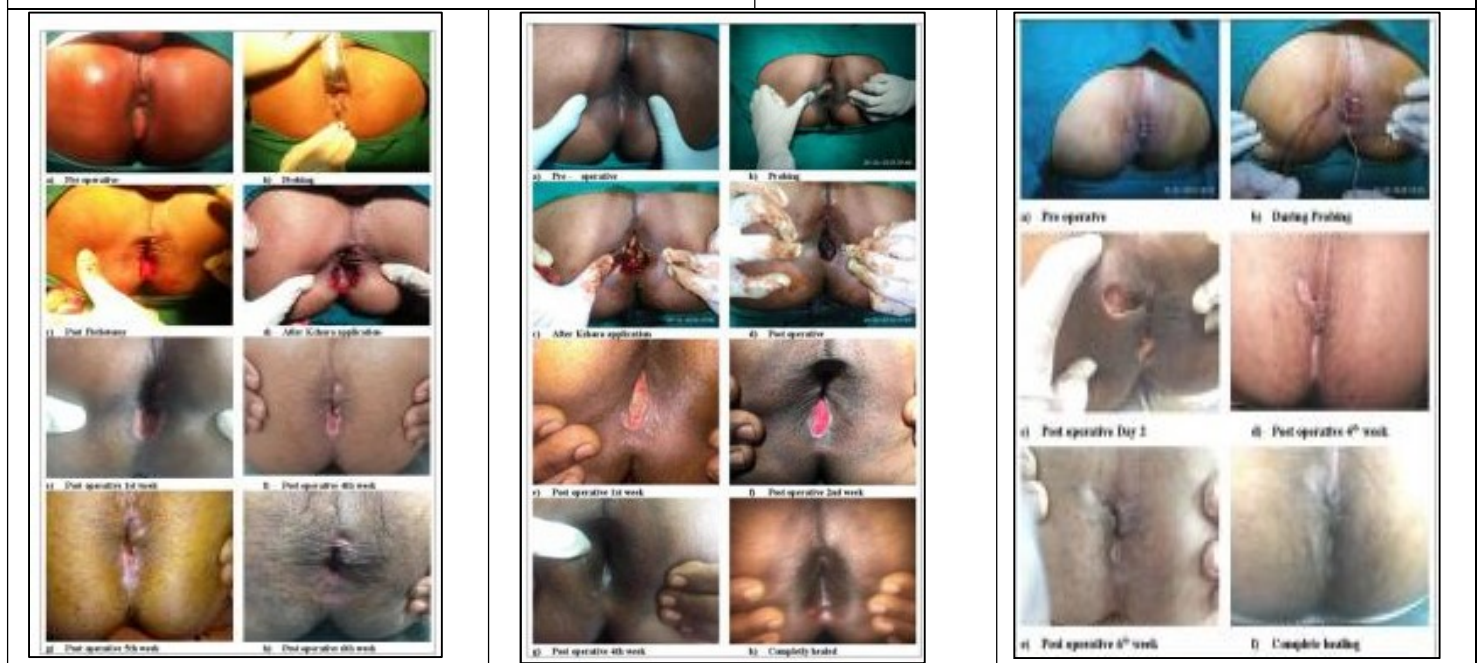

Figure3: CASE 3

Figure 4: CASE 4

Figure 5: CASE 5

DISCUSSION

In this case series the duration of healing is less as unhealthy granulation tissue is removed during fistulotomy and what is left is debrided by the *Tikshna Kshara*. As *Kshara* has *Shodhna* property, it also promotes healing.^[5]

Fistulotomy helps in complete removal of the fistulous tract and abscess cavity and *Tikshna Kshara* debrides the remaining unhealthy granulation and fibrous tissue at the base of the tract. It also cauterizes the branches which may be left undetected, thus preventing recurrence.

Panchvalkala kwath sitz bath helps to clean the pus discharge and associated debris from the tract and promotes drainage of pus from the tract. It helps to reduce local congestion and inflammation and thus relieve associated pain by enhancing local circulation which is necessary to promote healing.^[6] *Jatyadi tail Matra basti* was given as pain in any part of the body is due to vitiation of *Vata*^[7] and oil itself is *Vatashamak* in nature so reduces pain and it also lubricates the anal canal preventing constipation, eases the passage of stool and promotes wound healing. *Varun shigru gugglu* has antibacterial and anti-inflammatory properties so reduces pain and prevents infection.^{[8][9]}

CONCLUSION

On the basis of this case series it can be concluded that in Fistulotomy and *Ksharkarma*, post operative wound healed earlier without recurrence wound healing is less and there is early symptomatic relief. So, this can be good surgical intervention for the management of low anal fistula.

REFERENCES

1. Shastri A, Editor, (12th ed.). Commentary Ayurved Tatva Sandipika on Sushruta Samhita of Sushruta Sutras Sthana; Chapter 35 Verse 4. Varanasi: Chowkhambha Sanskrit Sansthan, 2001;....

2. Shastri A, Editor, (12th ed.). Commentary Ayurved Tatva Sandipika on Sushruta Samhita of Sushruta Chikitsa Sthana; Chapter 8 Verse 4. Varanasi: Chowkhambha Sanskrit Sansthan, 2001; 57
3. Shastri A, Editor, (12th ed.). Commentary Ayurved Tatva Sandipika on Sushruta Samhita of Sushruta Sutras Sthana; Chapter 11 Verse 7. Varanasi: Chowkhambha Sanskrit Sansthan, 2001; 46
4. Shastri R, Commentary Vidyotini on Charak samhita of Chikitsasthan; Chapter 12 Verse. 96-97. Varanasi: Chowkhambha Sanskrit Sansthan, 2009; 968
5. Khadkutkar et al. A Brief Review of Research Studies Conducted on *Panchavalkal*. Indian Journal of Ancient Medicine and Yoga, 2015; 8(2): 87-93
6. Shastri A, Editor, (12th ed.). Commentary Ayurved Tatva Sandipika on Sushruta Samhita of Sushruta Sutras Sthana; Chapter 17 Verse 12. Varanasi: Chowkhambha Sanskrit Sansthan, 2001;
7. Champak Medhi, Bhabesh Das "Evaluation of *Shigru (moringa oleifera lam)* seed in *Sangvahan* in post operative pain management" International Journal of Ayurveda and Pharma Research June 2017 - Vol 5 - Issue 6 - page no. 80-83
8. Okoli C.O. et al, Anti-inflammatory activity of pants, Journal of Natural Remedies. 3(1); 2003; p 1-30

Source of Support: Nil

Conflict Of Interest: None Declared

How to cite this URL: Monica Shrestha & T. S. Dudhamal: Clinical Efficacy Of Fistulotomy Followed By Ksharkarma In The Management Of Low Anal Fistula - A Case Series. International Ayurvedic Medical Journal {online} 2018 {cited January, 2019} Available from: http://www.iamj.in/posts/images/upload/166_170.pdf