

EXCISION OF PARTIAL SINUSECTOMY WITH KSHARSUTRA - A SINGLE CASE STUDY

Shital Shivaji Mane¹, Vidya Dharne²

3rd Year PG Student, Associate Professor Shalya Tantra Dept.

YMT Ayurvedic Medical College and Hospital Kharghar Navi Mumbai. Kharghar 410210, Maharashtra, India

Email: shital23mane@gmail.com

ABSTRACT

Pilonidal sinus is a condition greatly occur in recent years. pilonidal sinus is also called as jeep disease. It's a very common anorectal problem commonly arises from hair follicles of natal cleft. Post anal pilonidal sinus seldom presents itself & fills with infection. Successful management from prolonged wound care can be avoided in these patient's for prevention of recurrence in the surgical treatment. In this case report patient who suffered from pilonidal sinus since 1-2 months are treated with complete ayurvedic regimen. Although various surgical methods have been described for treating the sinus though I have chosen Ksharsutra method.

In this study, I have present a partial sinusectomy with Ksharsutra for pilonidal sinus. This case report showed that combined ayurvedic regimen is effective in the management of pilonidal sinus.

Keywords: Pilonidal Sinus, Ksharsutra, Ayurvedic Management.

INTRODUCTION

Pilonidal sinus is a sub-acute to chronic infection and painful condition in subcutaneous fatty tissue mainly in natal cleft of the Sacro-coccygeal region. Men's are more affected than females due to hairy portion. Although discharge and pricking pain is more common symptoms, associated with on & off fever.

In Ayurveda, Pilonidal sinus can be co-related with *Nadi-vrana*. And *Acharya* has advocated *Shastrakarma* along with intervention of *Ksharsutra* as one of the treatment modalities for *Nadi-vrana*. To avoid recurrence.

Taking this indication into consideration, in this present case study, patient having Pilonidal sinus was treated by *Ksharsutra* therapy.

The treatment proved ambulatory, time conserving, efficacious and cost effective in management of Pilonidal sinus.

Case Report: A male patient age 52 years. was selected from IPD of YMT ayurvedic medical college Kharghar Navi Mumbai.

General Examination: B.P-120/90 mmHg, PR-84 min, RR-18 min., Temperature -Afebrile, G.C.- fair, Having complaints: Pain

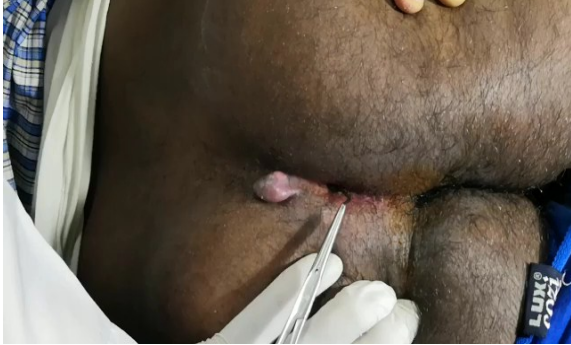Mild Fever, Swelling and tenderness

Inspection - (local examination)

2 external opening at Sacro-coccygeal region between cleft of buttock, Hyper granulation tissue pouting out at external opening (antero-superior), Discharge-

seropurulent pus discharge through opening, Swelling around natal cleft (mild), Tenderness ++, Hair projecting from the opening.

Secondary Examination done in lithotomy position to access any anal pathology or any anal connection.



Diagnosis-Pilonidal Sinus (*Shalyaj-nadivrana*)

Plan of Treatment:

Material-

Standard *Apamarga Ksharsutra* -having 21 coating.

[Method for preparation of *ksharsutra*]

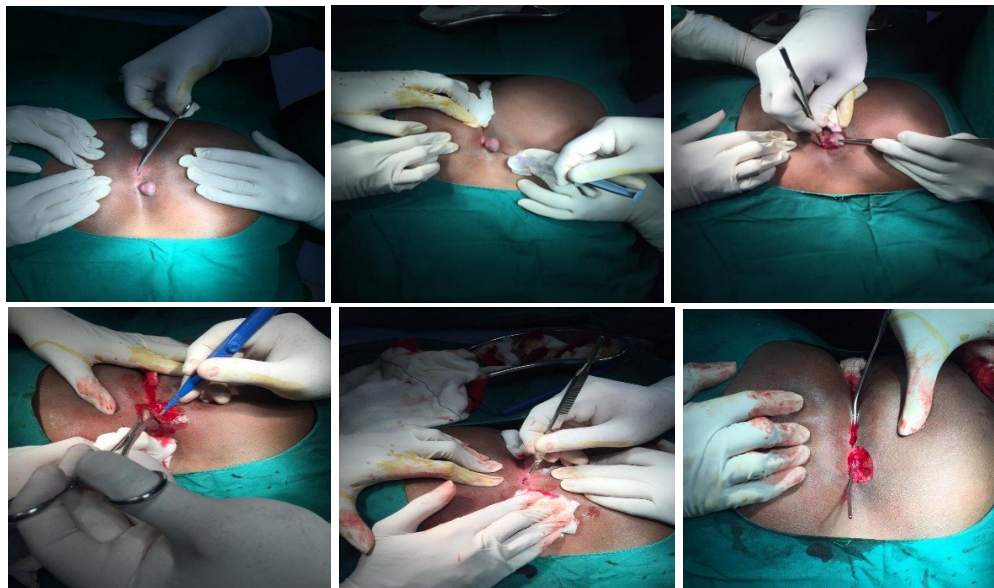
Ksharsutra is prepared taking Barber no.20 thread, coated with 3 herbal alkaline drugs namely -

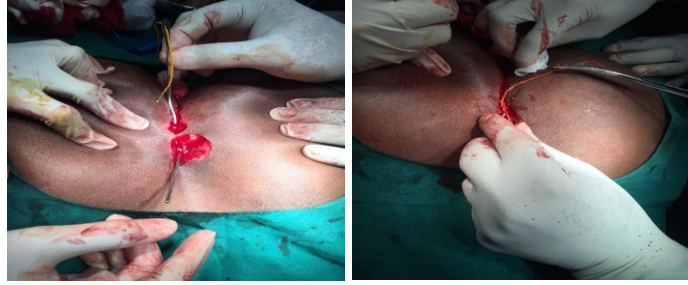1. Latex of *Snuhi* - (*Euphoria nerifolia*)-11 coating
2. Alkaline Powder (*Kshara*) of *Apamarga* -(*Achyranthus Aspera*)-7 coating
3. Powder of *Haridra* - (*Curcuma longa*)-3 coating

Methodology

All routine investigation was ruled out. CBC, Hb, blood sugar, serum creatinine, CT, BT, ECG, were within normal limit and HBsAg, HIV were nonreactive. All situations about disease and its management were explained to the patient and finally it was planned for *Ksharsutra* therapy under local Anesthesia as per day care procedure.

1. Patient was taken in prone position on OT table.
2. After proper cleaning and draping, local Anesthesia with 2% xylocaine was infiltrated nearby opening and in gluteal cleft
3. Re-assessment of extension of tract was done by probing
4. Removal of embedded Hair follicle, debridement of fibrous tissue/pus -unhealthy granulation tissue was removed through the opening on skin.
5. Tract was cleaned with Betadine and H₂O₂.
6. Probing done through opening and tract traced till its blind end and another opening was made over the skin up to the tip of the probe.
7. Probe removed through another opening after feeding of *Kshar* sutra and
8. *Kshar* sutra ligated appropriately.
9. Hemostasis achieved and tight bandaging was done.
10. After that changing of *Ksharsutra* done weekly and alternate dressing





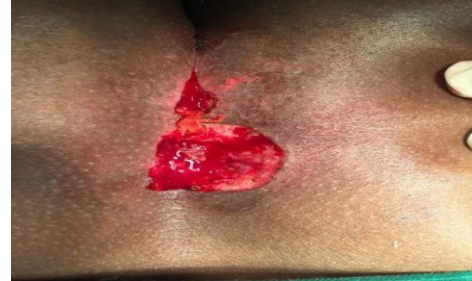Post Operative Treatment

- Oral Medication- Antibiotics: - Tab. Taxim – O 200mg orally 1 BD.
- Analgesic–Anti-inflammatory: Tab. EnzoFlam orally 1 BD...for 5 days

Followed by-

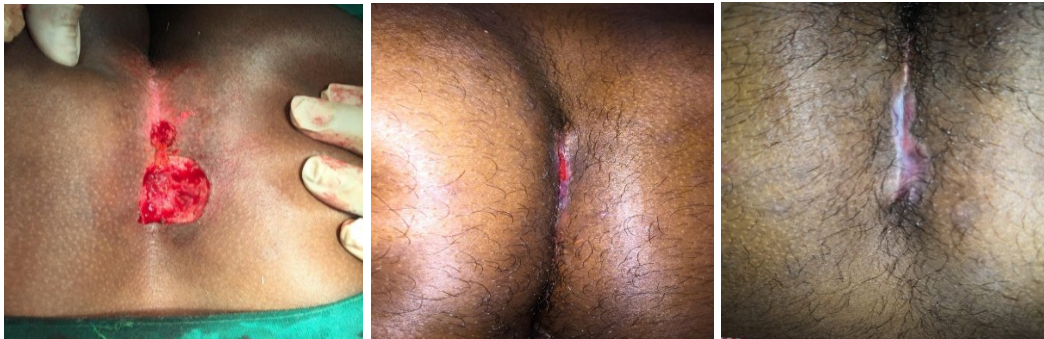
- *Aarogya vardhini vati* -250mg -2tab BD
- *Sukshmatripkala vati*-250mg -2tab BD
- *Gandharva Haritaki churna* -4 Gm HS orally with lukewarm water
- Daily dressing and cleaning with betadine and hydrogen solution– in Shalya OPD

Follow up- Observation



Patient was asked for changing *Ksharsutra* every 7th day (every week) until “cut through” of the tract. Kept continue to Ayurvedic medicine and Hot sitz bath. In 3 sitting (about 23 days) the tract was totally cut by *Ksar-sutra* and healing of wound was achieved.

Prognosis: The sinus track cut through and healed simultaneously by 3 weeks.



DISCUSSION

Treating pilonidal sinus instead of surgery with the help of ksharsutra is giving satisfactorily result. It is good n cost effective treatment. Ksharsutra is medicated thread. prepared by alkaline drugs like haridra powder snuhi latex and apamarga (ash). Reason for using this is these drugs having antibacterial antifungal and it helps in debridement of necrosed tissues and removes slough. Sinus tract cut through and healed simultaneously by 4 weeks. while this procedure anti-

inflammatory and antibacterial drugs should be given to reduce pain and inflammation.

Ksarsutra minimize rates of complication and recurrence and enables the patient to resume work and normal social activities as early as. It is acceptable treatment to the patient, extent of discomfort, impact upon body image and self-esteem.

CONCLUSION

Pilonidal sinus is correlated with *Nadivrana* and it can be considered under *Shalyaj-Nadivrana* (sinus due to foreign body). *Ksharsutra* can be used in the treatment for *Nadivrana chikitsa*. act as like, in this case study Pilonidal sinus was treated effectively by *Ksharsutra*. The treatment proved efficacious, time conserving, cost effective and reduced hospitalization

Hence, there is need to do number of cases of Pilonidal Sinus with this minimally invasive Ayurvedic para surgical procedure to establish *Ksharsutra* As- The Choice of Treatment.

REFERENCES

1. Sushruta Samhita Part-1, Chaukhamba Sanskrit Sansthan Varanasi Ambikadatta Tripathi. Chikitsa Sthan aadhaya 17-30 PG no.100-102. Aadhaya 17-17 PG no 99
2. Soumen das concise textbook of surgery 3rd edition PG no-1075.
3. Chakradatta Indradev Tripathi Chaukhamba Sanskrit bhavan Varanasi 22001 aadhaya 45 page no 267.
4. Bailey and love short practice in surgery 26th edition R. C. G. Russell page no 1244-1245.
5. Bharat Bhaishjya Ratnakara, Shree Nageendas Chhaganlal Shah Rasavaidya Vol 1 Ekaradi Rasa-prakarana Varanasi re-print edition 2010

Source of Support: Nil

Conflict of Interest: None Declared

How to cite this URL: Shital Shivaji Mane & Vidya Dharme: Excision Of Partial Sinusectomy With Ksharsutra - A Single Case Study. International Ayurvedic Medical Journal {online} 2020 {cited April, 2020} Available from: http://www.iamj.in/posts/images/upload/3424_3427.pdf